

# Carotid Endarterectomy without Angiography

W. ROBERT FELIX, JR. M.D.

ASSISTANT PROFESSOR OF SURGERY, HARVARD MEDICAL SCHOOL  
BOSTON, MA

ATTENDING SURGEON, BRIGHAM AND WOMEN'S HOSPITAL  
BOSTON, MA

MEDICAL DIRECTOR, VASCULAR DIAGNOSTIC CENTER OF BOSTON,  
CHESTNUT HILL MEDICAL CENTER  
CHESTNUT HILL, MA

**E**ach new technique for achieving and clarifying the diagnosis of arterial disease has stimulated an effort to establish its value as a tool for guiding surgical intervention. Noninvasive studies such as oculoplethysmography (OPG), phonoangiography, Doppler ultrasound spectral analysis, B-scan ultrasound, duplex ultrasound, computed tomographic (CT) scanning, magnetic resonance imaging (MRI), and transcranial Doppler have been seductive because these tools require no invasion of the body or the artery of interest and are, therefore, eminently safe.

Arteriography has been the standard for comparison since its introduction by Dos Santos and colleagues in 1931.<sup>1</sup> An arteriogram provides optimal information on the degree of stenosis and presence of proximal or distal (tandem) lesions. Concomitant pre- and post-stenotic pressure measurements are valuable and can be performed in conjunction with arteriography. However, the arteriogram carries risks that include the need to penetrate into the

artery of interest (or a nearby artery), dye allergy and dye load. These risks have been reported as 0.5% deaths and 1.2% "serious complications";<sup>2</sup> 6.8% transient neurologic episodes;<sup>3</sup> and 5.4% permanent cerebral complications.<sup>3</sup> The cost of arteriography ranges from \$2500 to \$5000. In addition, arteriography does not have an acceptable sensitivity and specificity for identification of atheromatous ulcer and provides little or no information about the pres-

ence of intra-plaque hemorrhage. These relative disadvantages of arteriography further stimulate the search to find accurate noninvasive tools to guide surgical therapy. This chapter discusses these tools and presents a rational approach for their use in the selection of patients for carotid endarterectomy.

### HEMODYNAMIC TECHNIQUES

Ocular pneumoplethysmography (OPG-GEE)<sup>4,5</sup> and oculoplethysmography Karchner-McRae (OPG-KM)<sup>6</sup> are differential measurements of the pressure or amplitude and timing of pulse wave forms as measured by transducers placed on the surface of the eye. McDonald and colleagues reported that a positive diagnosis was obtained in 97% of patients with a 50% obstructive stenosis with OPG-GEE.<sup>7</sup> Comparative studies disclose the collective sensitivity of OPG-KM to be 61% for lesions in the 40% to 60% stenosis range, and sensitivity of OPG-GEE to be 85% for lesions in the 50% to 60% stenosis range.<sup>8,9</sup> The OPG techniques are unable to distinguish between high-grade stenosis and occlusion and are unable to detect bilateral occlusion.<sup>10</sup>

Doppler interrogation of the supra-orbital (or frontal) arteries is another

tool for detecting reduced flow into the distal carotid artery. Antegrade flow (toward the transducer placed over the artery at the orbit) detected with directional Doppler is normal. Retrograde flow suggests that a significant internal carotid stenosis is present. Increase of flow signal on compression of branches of the external carotid temporal, facial, and angular artery (ECA) is normal, and diminished flow signals on compression of these potential collateral vessels suggest significant stenosis of the ipsilateral internal carotid artery (ICA). Barnes and colleagues, in comparison studies with supraorbital Doppler and arteriography on 152 arteries, found that the directional flow alone identified 95% of lesions greater than 75% stenosis, but only four of 63 lesions less than 75% stenosis.<sup>11,12</sup> They also found that directional flow plus compression of potential collaterals detected 98.7% of lesions with stenosis greater than 50%, while temporal artery compression alone identified only 64% of these lesions. No false-positive examinations were noted.

Despite the reported impressive results for detecting significant stenosis (>50%) with these hemodynamic tests, they all are unable to distinguish the degree of stenosis, are falsely negative in the presence of generous collaterals by way of the circle of Willis, and are unable to identify tandem lesions. These hemodynamic studies may have some value as screening tools because they are simple, inexpensive, and able to identify significant stenosis. However, these tests cannot individually or collectively replace arteriography because they cannot provide detailed anatomic information, cannot clearly distinguish between high-grade stenosis and obstruction, and provide no information about ulcerated plaques or intra-plaque hemorrhage.

### TRANSCRANIAL DOPPLER

Transcranial Doppler sonography is accomplished using low-frequency Doppler (2 MHz) and ports by way of the orbit, foramen magnum, or thin area of the temporal bone. A pulsed Doppler signal is analyzed by sound spectral technique, and presence of stenosis can be inferred from the frequency shifts as the pulsed Doppler "interrogates" an artery. Early anecdotal reports,<sup>13</sup> and later validation studies,<sup>14</sup> suggest that lesions of the vessels at the

base of the brain can be accurately interrogated for the presence of stenosis. This technique holds promise to assist in detecting tandem lesions distal to cervical carotid stenosis.

### DOPPLER SPECTRAL ANALYSIS

Lesions below the clavicle are difficult to identify because of the limited depth of tissue penetration by Doppler carrier frequencies (5.0 MHz to 7.5 MHz) used in the duplex ultrasound scanner. Felix and colleagues showed that evidence of disturbed flow, such as spectral broadening associated with stenotic lesions, can be detected up to 20 diameters (15 cm to 20 cm in most medium-sized arteries) distal to the lesion.<sup>15</sup> Changes in the spectral analysis of the center stream pulsed Doppler signal suggest disturbed flow associated with a lesion. Thus, lesions at the intra-thoracic origin of the common carotid artery (CCA) may be identified by interrogation with Doppler at or above the level of the clavicle. The degree of stenosis cannot be accurately determined, but is probably more than 20% when the study is positive. Transcranial Doppler and spectral analysis of Doppler signals from the CCA may be useful in detecting the presence of intra-cranial and intra-thoracic tandem lesions, respectively.

### MINIMALLY INVASIVE TECHNIQUES

Digital subtraction angiography (DSA) is achieved by injecting a small amount of contrast medium and then building an image using digital computer technology. Intravenous injection has been used to visualize the carotid arteries; however, the image quality has been disappointing with up to 20% of studies lacking diagnostic quality.<sup>16</sup> Arterial digital subtraction studies are gaining acceptance for their diagnostic quality; however, except for the smaller dye load, arterial digital subtraction suffers from the same disadvantages as standard arteriography.

MRI can provide superior blood flow estimates in tissue sections and across vessel segments.<sup>17,18</sup> MRI arteriography has not proved to be of diagnostic quality. The addition of contrast material has not, to date, improved the MRI technique sufficiently to supplant arteriography.

CT scanning has proved to be useful in evaluation of brain tissue for evidence of infarct and other intra-cranial pathologic

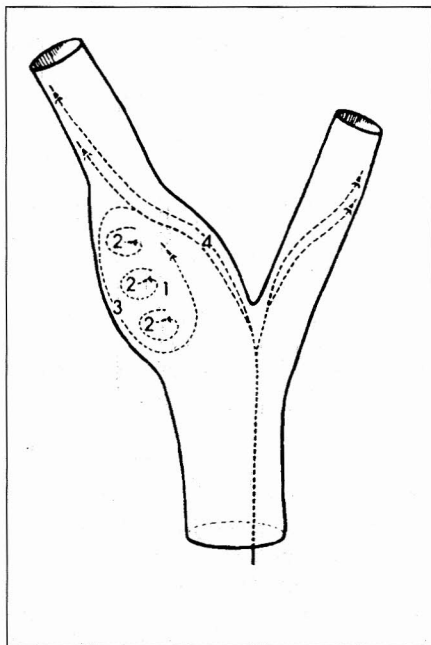


Figure 1. Schematic diagram of complex secondary blood flow velocity patterns in carotid sinus region of normal subject exhibiting flow separation zone (1), helical flow (2), flow reversal (3), and antegrade flow (4). (Reprinted by permission: Nichols SC, Phillips DJ, Primozich JF, et al. Diagnostic significance of flow separation in the carotid bulb. *Stroke* 1988; 20(2):175-82.)

disorders such as tumor or aneurysm. This tool has not been useful in intra- or extra-cranial vascular evaluation.

## DUPLEX ULTRASOUND

### Correlation of Ultrasound and Arteriography (the Validative Studies)

#### Instrumentation

The Duplex ultrasound instrument combines real-time B-mode scanning with pulsed Doppler. All current instruments also offer on-line time-frequency presentation (sound spectral analysis) of the Doppler signal.<sup>16,19</sup> These instruments are capable of presenting a high-quality, gray scale image of the neck arteries. Doppler signals can be obtained from a sample as small as one cubic millimeter at any site within the vessel lumen. The carotid artery can be examined from the clavicle to the angle of the jaw, and a composite anatomic and hemodynamic presentation can be constructed of the CCA, ICA, and ECA.

Before we could consider using this tool as the exclusive guide to surgical intervention, it required validation by comparison with arteriograms and pathologic specimens removed at carotid endarterectomy. This latter comparison becomes critical as we consider extending the indications for surgery to include atheromatous ulcer, intra-plaque hemorrhage, and other characteristics of the intimal plaque not well-identified by arteriogram.

#### Estimation of Stenosis

The degree of stenosis in an arterial study can be determined by the duplex ultrasound from the B-scan image or from analysis of the Doppler signals. The technique has been well presented elsewhere.<sup>16,20,21</sup> Primary features of the examination are emphasized.

1. All studies should be conducted by experienced personnel under supervision of knowledgeable physicians.
2. All initial studies are bilateral.
3. The extracranial arteries are scanned from clavicle to angle of the jaw in at least two planes (transverse and longitudinal), with additional oblique views to clarify any abnormalities encountered.
4. All studies are recorded on videotape for later review.
5. Doppler signals are obtained from the center of the flow stream in the CCA, carotid bulb, distal ICA, dis-

tal ECA, and within the residual lumen of any lesion encountered.

6. The residual lumen diameter of any stenotic lesion is estimated, as is the diameter of the vessel just distal to the lesion.

#### Diameter Estimates

Following are the two commonly used methods for estimating the degree of stenosis based on diameter measurements.

The first method compares diameter of the stenotic area to the diameter of

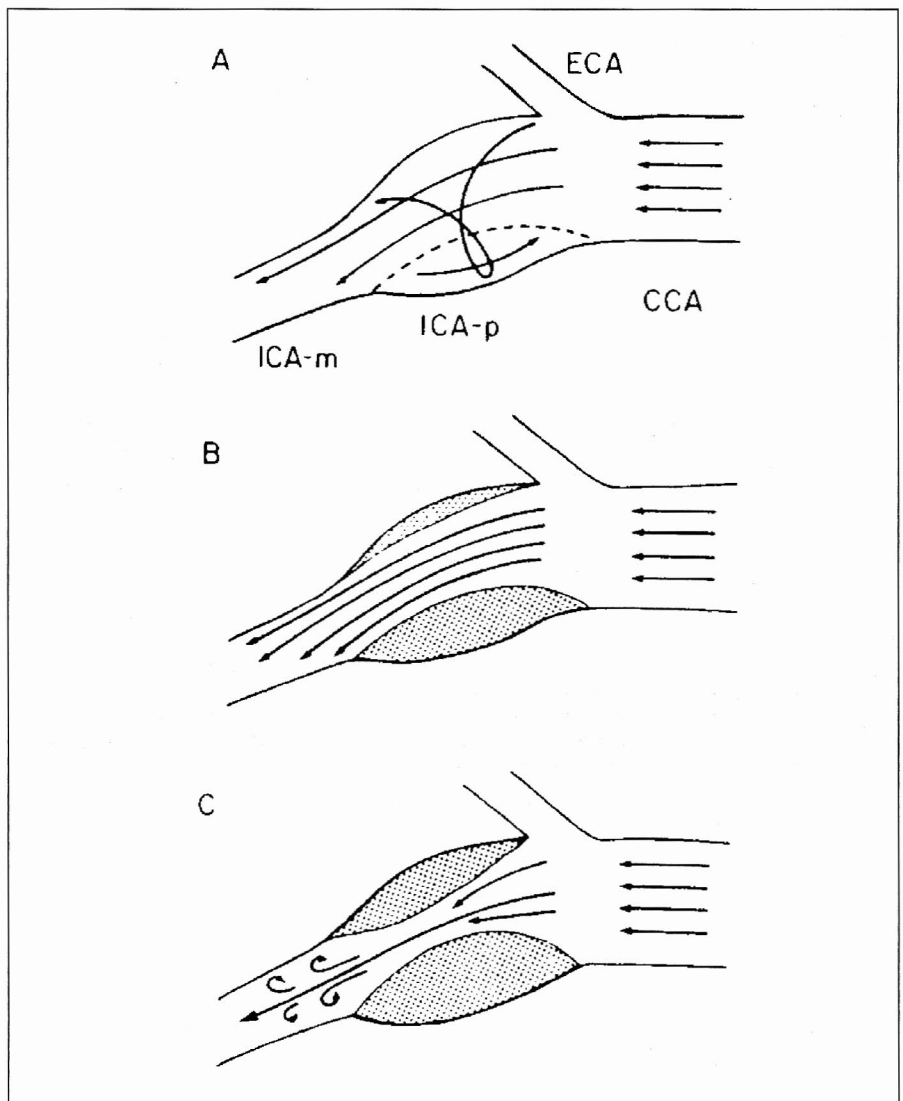
the artery distal to the lesion.

$$\text{Stenosis} = \left(1 - \frac{\text{residual lumen diameter}}{\text{distal lumen diameter}}\right) \times 100$$

The second method compares the diameter of the stenotic lesion to the estimated diameter of the vessel at the site of the lesion were it to be free of stenosis.

$$\text{Stenosis} = \left(1 - \frac{\text{residual lumen diameter}}{\text{estimated normal diameter}}\right) \times 100$$

The first method is the most commonly used. The North American



Figures 2a,b,c. Schematic diagram of hypothesized primary blood flow patterns as function of plaque deposition.

Figure 2a. Normal carotid sinus with unidirectional antegrade flow along apical divider, flow separation zone occupying sinus region opposite flow divider, circumferential or helical flow within sinus, and transient flow reversal along outside wall of sinus. Undiseased carotid bulb probably has the most complicated flow patterns of all.

Figure 2b. With minimal to moderate disease, flow separation zone is partially filled, resulting in marked attenuation of secondary flow patterns caused by branch angle and dilated segment of sinus.

Figure 2c. Further narrowing reduces effective cross-sectional area within sinus region is less than that of distal internal carotid artery (ICA). This produces increased peak velocities at site of narrowing and small vortices distal to narrowed segment, which are typical of poststenotic secondary flow patterns. ECA, external carotid artery; CA, common carotid artery; p, proximal; m, mid.

(Reprinted by permission: Nichols SC, Phillips DJ, Primozich JF, et al. Diagnostic significance of flow separation in the carotid bulb. *Stroke* 1988; 20(2):175-82.)

Symptomatic Carotid Endarterectomy Trial (NASCET), Veterans Affairs Cooperative Trial, and the Asymptomatic Carotid Artery Stenosis Study Group (ACAS) all use this method. The method will usually estimate the stenosis at a lesser value than the second approach, which is used in the European Carotid Surgery Trial (ECST).

### Area Estimates

Percent stenosis based on area measurements of residual lumen and estimated area of normal lumen can be accomplished on most modern instruments. Because of the difficulty in identifying the vessel wall in the presence of a lesion, however, this method has not

been reproducible enough for comparative or serial studies.

### Separation of Normal from Mild Stenosis

A close study of the flow patterns in the carotid bulb by Nichols and colleagues showed that alterations in the flow can help to separate patients with minimal disease from those who are normal (Figure 1).<sup>22</sup> In the carotid bulb, the normal flow velocity pattern is antegrade near the flow divider and is retrograde (mild turbulence) with flow boundary separation in the posterior lateral aspect of the bulb. This normal pattern is replaced by a more ordered flow pattern (loss of the boundary separation)

as mild (20% or less) stenosis develops (Figure 2).<sup>22</sup> Nichols and colleagues reported a series of 20 symptomatic patients, all of whom had flow boundary layer separation in the bulb of both carotid arteries.<sup>22</sup> The arteriograms of 35 of these carotid arteries were normal (77%); four had 20% or less stenosis by smooth plaque. The cause of the symptoms was found elsewhere in 19 of the 20 patients.

Spectral broadening (filling in the clear area or "window" in the normal sound spectral display) is also indicative of stenosis.<sup>15,16</sup> However, spectral broadening has not been determined to be useful in estimating the extent of stenosis.

### Doppler Frequency Correlation with Stenosis

Doppler frequency data can be used to estimate the degree of stenosis after the data are "normalized" to a 60° angle and 5-MHz carrier frequency. Blackshear and colleagues<sup>20</sup> noted that a peak systolic frequency exceeding 4 KHz (125 cm/sec) and an end-diastolic frequency below 4.5 KHz are associated with stenosis of greater than 50% (Figure 3).<sup>16</sup> If the end-diastolic frequency was greater than 4.5 KHz, they found a greater than 80% stenosis (Figure 4).<sup>16</sup>

Another method of determining stenosis by frequency analysis involves the use of ICA/CCA ratios. If the ratio of the peak systolic velocity of the ICA and CCA is less than 0.8, the vessel is probably normal. An ICA/CCA peak systolic velocity ratio greater than 1.5 suggests a stenosis greater than 50%. Moneta and colleagues reported that the ICA peak systolic velocity/CCA peak systolic velocity ratio greater than 4.0 is the best criterion for identification of stenosis between 70% and 99%.<sup>23</sup> The sensitivity was 91%; specificity, 87%; positive predictive value, 76%; negative predictive value, 96%; and overall accuracy, 88%. Table 1 summarizes these approaches to determining degree of stenosis.

The results from color Doppler study seem to be following those of standard duplex ultrasound. Barnes and colleagues found that a mean peak systolic velocity greater than 110 cm/sec and an ICA mean peak systolic velocity/CCA mean peak systolic velocity ratio greater than 1.4 represent the significance line between less than and greater than 60% stenosis.<sup>24</sup>

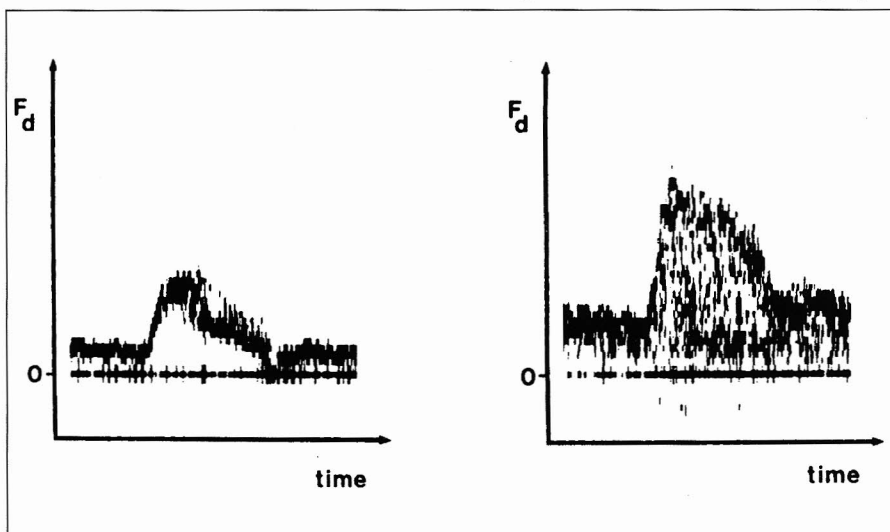


Figure 3. The velocity spectra on the left were from the common carotid artery. Those on the right are of the type noted with a 16 to 49% stenosis. The peak frequency (Fa) is below 4 KHz (125 cm/sec). The major diagnostic criterion used is marked spectral broadening, which obliterates the systolic window. (Reprinted by permission: Strandness DE Jr. Extracranial arterial disease. In: Strandness DE Jr, ed. *Duplex Scanning in Vascular Disorders*. New York, NY: Raven Press, 1990:62-120.)

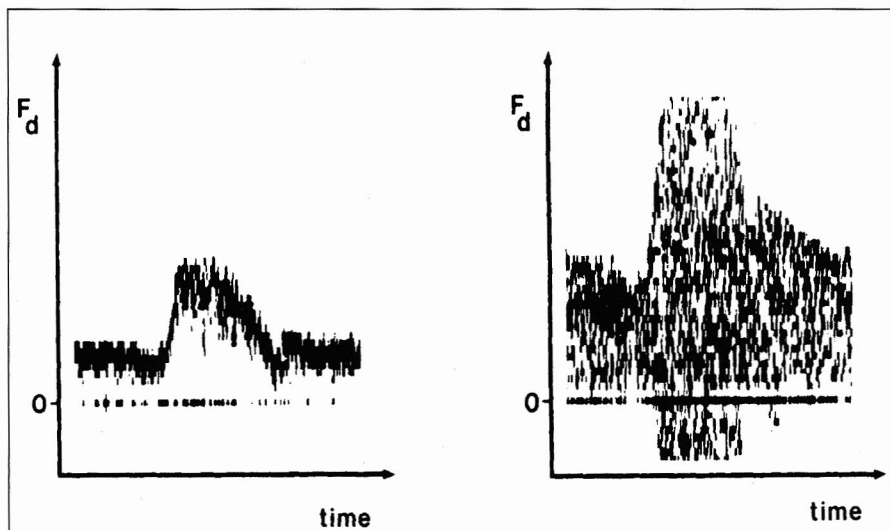


Figure 4. The velocity spectra on the left were from the common carotid artery. Those on the right were from a 50 to 79% stenosis of the internal carotid artery. The peak systolic frequency (Fa) exceeds 4 KHz (125 cm/sec). (Reprinted by permission: Strandness DE Jr. Extracranial arterial disease. In: Strandness DE Jr, ed. *Duplex Scanning in Vascular Disorders*. New York, NY: Raven Press, 1990:62-120.)



Faught and colleagues reported that using color flow duplex scanning, a peak systolic velocity less than 130 cm/sec and an end-diastolic velocity less than 100 cm/sec best predicted a 50% to 69% stenosis; sensitivity, 92%; specificity, 97%; positive predictive value, 93%; negative predictive value, 99%; and overall accuracy, 97%. A peak systolic velocity greater than 130 cm/sec plus an end-diastolic velocity greater than 100 cm/sec predicted a stenosis of 70% to 99%: sensitivity, 81%; specificity, 98%; positive predictive value, 89%; negative predictive value, 96%; and overall accuracy, 95%.

One must caution against slavishly using any one technique for estimation of stenosis. The "diameter methods" are subject to error in the presence of extensive intimal disorders and the "velocity or frequency methods" are subject to error due to Doppler incident angle estimation, sample size, Doppler carrier frequency, and aliasing. All methods are subject to inter- and intra-observer variation. It is important that each laboratory develop a standard examination protocol, validate their protocol, and continuously re-evaluate their results.

### TOTAL OCCLUSION DILEMMA

High-grade stenosis sufficient to reduce flow to near zero is often mistaken for total occlusion by the duplex ultrasound technique because the Doppler instrument is not sensitive to flow velocities below 6 cm/sec. Because the results of carotid endarterectomy in chronic occlusion are generally poor, occluded arteries are not operated upon. However, a patient with a non-occluding, high-grade stenosis incorrectly diagnosed as occlusion may be denied the opportunity for corrective surgery. To avoid this error, attention must be paid to certain characteristics of the Doppler ultrasound signals associated with an occluded vessel.

Figure 5 depicts the important Doppler ultrasound findings in total occlusion of the ICA.<sup>16</sup> Two characteristics of the Doppler signal sound spectrum are consistent and rather specific for complete occlusion of the ICA:

1. The wave form in the CCA returns to baseline during diastole. Thus the wave form (or sound spectral display) in the CCA with complete occlusion of the ipsilateral ICA resembles that of a peripheral artery (ie, flow returns to baseline during diastole). The CCA and

ECA become a continuous system supplying the peripheral arteries of the face and head, and the Doppler wave form in CCA and ECA are identical.

2. The presence of a "thumping" sound. This sound is heard when the examiner is sampling from the area immediately proximal to the occlusion (Figure 5).<sup>16</sup> This phenomenon occurs because no net forward flow is present at that site. The "thump" represents the to-and-fro movement of the occluded segment.

Two less-specific, but often identifiable, indirect indications of complete ICA occlusion are: (1) increased flow in the contralateral CCA, and (2) increased flow in the ipsilateral ECA. These phenomena occur because in both cases these arteries are the major collaterals that supply blood to the ipsilateral hemisphere. Both of these findings are not specific for internal carotid occlusion because stenosis at the examining site can produce increased flow velocity. This is especially true regarding the ipsilateral ECA because the origin of that vessel is

### Characterization of Degree of Stenosis

Normal:	Flow reversal in carotid bulb, no spectral broadening (clear "window" in spectral display), ICA/CCA ratio <0.8
1%-15% stenosis:	No flow reversal in carotid bulb
16%-49% stenosis:	Spectral broadening
50%-79% stenosis:	Spectral broadening, peak systolic frequency exceeds 4 KHz (125 cm/sec), end-diastolic frequency below 4.5 KHz, ICA/CCA ratio >1.5
80%-99% stenosis:	Spectral broadening, end-diastolic frequency exceeds 4.5 KHz (140 cm/sec), ICA/CCA ratio >4.0

ICA = internal carotid artery

CCA = common carotid artery

Table 1.

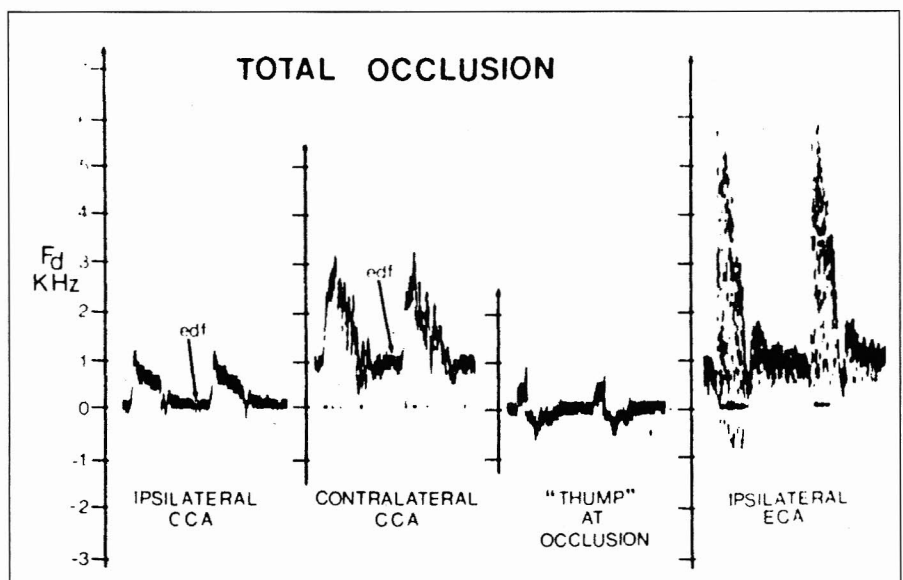


Figure 5. The major findings when the internal carotid artery (ICA) is occluded. In the left panel, flow in the common carotid artery (CCA) at end-diastole goes to zero. Flow in the contralateral carotid artery will be higher than usually found, since it now supplies both hemispheres. When the sample volume is placed at the base of the occlusion, a "thump" may be heard that reflects no net forward flow at that point. Finally, in the right panel, flow in the ipsilateral external carotid artery (ECA) might be increased; it now serves as a major collateral source for the brain. However, caution is urged, since a stenotic lesion can also give rise to the same velocity pattern, EDF, end-diastolic frequency. (Reprinted by permission: Strandness DE Jr. *Extracranial arterial disease*. In: Strandness DE Jr, ed. *Duplex Scanning in Vascular Disorders*. New York, NY: Raven Press, 1990:62-120.)

often involved in the same pathologic process that produced the ICA lesion.

If the examiner relies on measuring quantitative flow (velocity x area) rather than flow velocity alone (estimated from frequency shift), these errors can be minimized. Thus, if a measured increase of flow volume is present in the contralateral CCA or ipsilateral ECA, one can have some degree of confidence that the suggested ICA occlusion (ie, no flow velocity distal to the lesion) is, in fact, real.

### Surgical Correlations (Pathologic Validative Studies) Stenosis

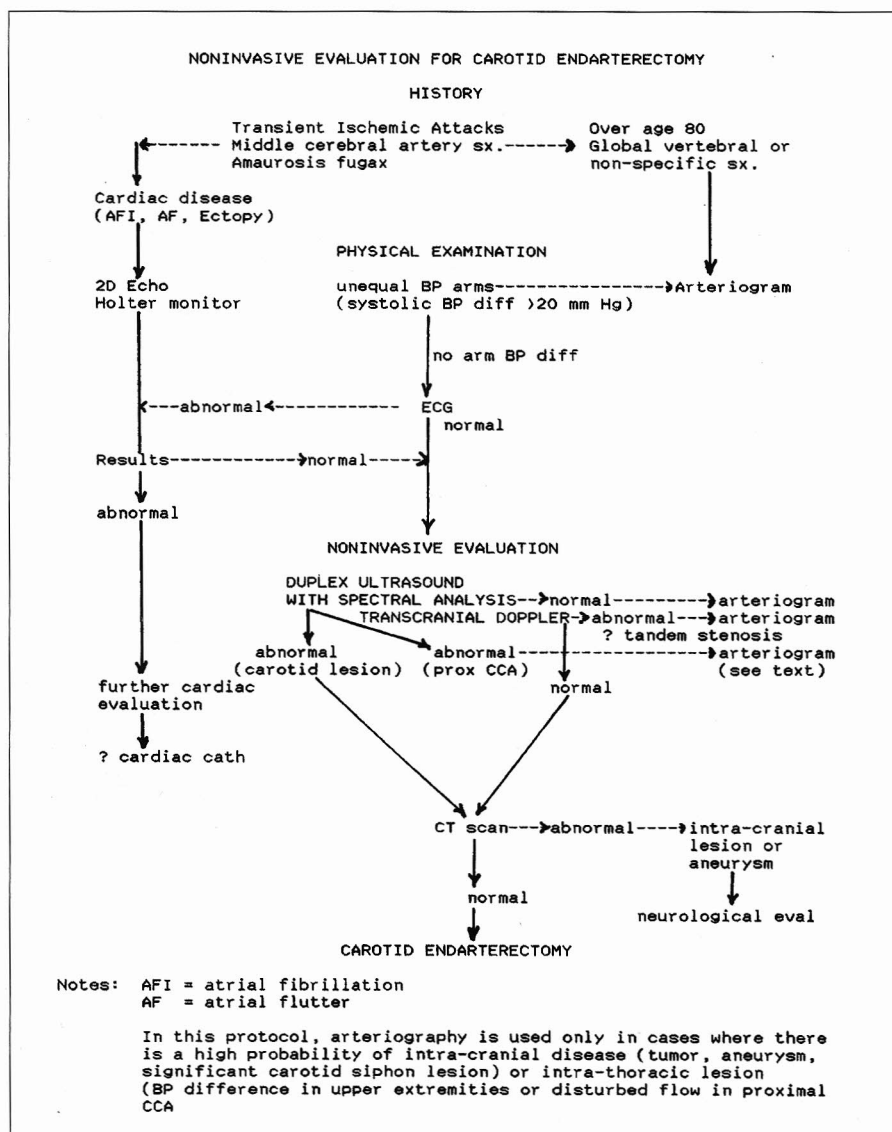
Numerous studies have confirmed that duplex ultrasound enjoys a high degree of accuracy when compared to arteriography in determining the pres-

ence of a hemodynamically significant stenosis ( $>50\%$ ). Most of these reports compare duplex ultrasound with arteriogram and record sensitivities for greater than 50% stenosis in the ranges of 91% to 95%.<sup>16,20,24,25</sup> Correlation with operative pathologic findings is necessary before ultrasound can be used to plan surgery. Goodsen and colleagues compared duplex ultrasound and arteriography with 78 endarterectomy specimens and found the sensitivity of ultrasound was 99% and arteriography was 91%.<sup>26</sup> Seven lesions correctly identified by ultrasound were missed by arteriography. The sensitivity of ultrasound was markedly superior to arteriography in identification of ulceration (90% versus 54%) and in identification of intimal surface abnormalities (92% versus 64%). Geuder and col-

leagues reviewed 100 cases studied by duplex ultrasound and arteriography, but used arteriography as the final arbitrator for surgery on 80 patients with greater than 80% stenotic lesions.<sup>27</sup> Three patients had 80% stenotic lesions by ultrasound but not on arteriogram. They were not operated on, so we do not know what the pathologic findings were. Five other patients had the surgical approach altered by the finding on arteriogram. Two tandem lesions with stenosis equal to the carotid lesion were not operated. Three patients had other extracranial abnormalities that required an altered surgical approach. Because we do not know the pathologic features in the five patients not operated on, we can only conclude that this group of patients had a correct diagnosis by ultrasonography in 80 endarterectomies. Weintraub and colleagues correlated 37 endarterectomy specimens with duplex ultrasound and arteriography.<sup>28</sup> They found a 97% accuracy rate with ultrasound and only a 70% accuracy rate with arteriography. These studies strongly suggest that duplex ultrasound is comparable to arteriography in evaluating the stenotic lesion.

### Atheromatous Ulcers

Cerebral ischemia resulting from progressive stenosis has traditionally been believed to be the principle pathophysiologic process for the development of cerebral symptoms. We now know that the occurrence of an ulcer in an atherosclerotic plaque provides a source of fibrin-platelet thrombi and the sequelae associated with embolization.<sup>29</sup> Duplex ultrasound is better able to identify these ulcers than arteriography. Goodsen and colleagues reported sensitivity for detection of ulceration as 90% by ultrasound and only 54% for arteriography.<sup>26</sup> Weintraub and colleagues reported ten clinically active ulcerative plaques missed by arteriography.<sup>28</sup> O'Donnell and colleagues examined 68 operative specimens and found that ultrasound identified 87% of ulcers, while arteriography identified only 59%.<sup>30</sup> Edwards and colleagues reported only 60% of ulcers identified at surgery as being seen on the preoperative arteriogram.<sup>31</sup> Of these, 15% were in plaque appearing smooth on arteriography. Senkowsky and colleagues reported 21 patients with transit ischemic attacks (TIAs) and normal arteriograms who had ulcerative lesions identified by B-mode ultrasound.<sup>32</sup> All the ulcers were found at



surgery to be associated with 20% to 50% stenosis. Johnson and colleagues identified 184 patients with atheromatous ulcers using duplex ultrasound and followed them for one year.<sup>33</sup> Patients with ulcers less than 2 mm deep did not develop symptoms and some ulcers appeared to heal. Thirty percent of patients with ulcers 2 to 4 mm deep developed symptoms. All patients with ulcers greater than 4 mm deep were symptomatic at discovery and were operated upon.

### Plaque Characterization

The atheromatous plaque can also be characterized as soft, heterogenous, or calcified by duplex ultrasound. Reilly and colleagues found that 100% of ulcers and 91% of intra-plaque hemorrhages were in heterogeneous plaques removed at surgery.<sup>34</sup> Ultrasound identified 82% of the intra-plaque hemorrhages. Plaques filled with lipid or cholesterol accounted for the 12% false-positives. Johnson and colleagues, in their study of 297 carotid lesions, found that the highest risk for symptoms was in the patient with a soft plaque and 75% stenosis.<sup>35</sup> Only 10% of calcified plaques was associated with symptoms. In their five-year follow up,

the development of new symptoms occurred with greatest frequency in the group with 75% stenosis and soft plaque.<sup>36</sup>

Duplex ultrasound is comparable to arteriography in estimation of stenosis, slightly superior in identification of atheromatous ulcers, and decidedly superior in characterizing the plaque or identification of intra-plaque hemorrhage.

### CLINICAL STUDIES SUPPORTING ENDARTERECTOMY WITHOUT ARTERIOGRAPHY

#### Patient Selection

An algorithm for selecting patients for carotid endarterectomy with arteriography has been proposed by Akers and colleagues (Figure 6).<sup>37</sup> The approach is based on a few assumptions: (1) cardiac sources of emboli can be ruled out with appropriate noninvasive studies; (2) carotid siphon stenosis is probably not significant, and relief of symptoms will occur even in the presence of a siphon lesion; (3) significant intra-thoracic stenosis will be manifested by an arm blood pressure difference of more than 20 mm Hg; and (4) a normal CT scan will rule out a recent

stroke and identify other intra-cranial disease. To support their thesis, Akers and colleagues cited their own series of 784 intra-cranial arteriograms in which only 6% (46 patients) had carotid siphon stenosis ranging from 5% to 70%.<sup>37</sup> All 31 patients who underwent carotid endarterectomy were relieved of their symptoms. Roederer and colleagues could not show a relationship between severity of carotid siphon stenosis and success rate of carotid endarterectomy.<sup>38</sup> Schuler and colleagues found no difference in operative mortality rate, risk of stroke, and relief of symptoms between patients with and without carotid siphon stenosis.<sup>39</sup> Moore argued that removal of the source of emboli at the carotid bifurcation is such an important goal that patients with carotid siphon stenosis should not be denied the procedure because there is no apparent effect on their perioperative morbidity.<sup>40</sup> One might also argue that removal of the carotid source of emboli reduces the risk of embolic occlusion of the ICA at the siphon stenosis.

Akers and colleagues cited their study of 1000 patients with aortic arch arteriograms.<sup>41</sup> After removal of 12 patients with arm pressure differences

### Summary of Clinical Experience

AUTHOR	REF	DATE	#PATIENTS	END	REASONS FOR OP W/O ARTERIOGRAM					
					DYE	URG	STEN	PROG	AF/IH	PREF
Blackshear et al.	(42)	1982	5	5	5					
Gonzales et al.	(43)	1984	16	16						16
Crew et al.	(44)	1984	65	65	3	14	17	12		19
Thomas et al.	(45)	1986	30	32	2	3		7		18
Walsh et al.	(46)	1986	28	28					28*	
Moore et al.	(47)	1988	29	32	7	8				14
Hill et al. <sup>†</sup>	(48)	1990	101	130						101
Cartier et al.	(49)	1993	118	130	13		27			78

\*These patients had arteriography, but ulcerated lesion was identified in only 17. Operation was based on ultrasound finding.

†This series has been extended to 347 operations to date (see text).

END	=	Endarterectomies
DYE	=	Dye allergy and patients who were in renal failure at the time of study
URG	=	Urgency (ie, stroke in evolution, early postoperative reocclusion, early re-stenosis, crescendo TIA), urgent other surgery (unstable angina and CABG, acute occlusion, or aneurysm elsewhere)
STEN	=	Extreme stenosis
PROG	=	Progress of lesion on serial examination
AF/IH	=	Amaurosis fugax or intraplaque hemorrhage
PREF	=	Surgeons' preference that includes confidence in duplex examination (personal success), patient fear of arteriogram, poor cooperation, and technical consideration (severe lower-extremity lesion precluding access, arteriogram technical failure)
TIA	=	Transient ischemic attack
CABG	=	Coronary artery bypass graft

Table 2.

greater than 20 mm Hg, only six of 988 (0.6%) were determined to have significant intra-thoracic stenosis, none of whom required surgery over a two-year follow-up period. Of 87 patients with vertebral artery disease, six required surgical treatment. The authors propose that an aortic arch study be performed in patients with cerebral symptoms who have *negative* noninvasive studies. It should be noted that careful duplex ultrasound evaluation of the vertebral arteries can show lesions in that location. In our modification of their algorithm, the transcranial Doppler has been added to evaluate carotid siphon stenosis.<sup>14</sup> We have also added sound spectral analysis of ultrasound signals from the proximal carotid artery as a supplement to arm blood pressure difference to identify the presence of disturbed flow caused by intra-thoracic lesions.<sup>15</sup>

### Clinical Experience

Carotid endarterectomy without arteriography has been a logical goal since the introduction of noninvasive studies, but has become feasible only with development of the present generation of duplex ultrasound instruments and the validative studies noted above. Patients with dye allergy, or renal disease patients, were the most likely early candidates (Table 2). Blackshear and colleagues reported five patients allergic to contrast material who had five carotid endarterectomies based solely on pulsed Doppler "ultrasonic arteriography" and real-time spectral analysis.<sup>42</sup> The ultrasound findings were confirmed at endarterectomy in all five arteries.

Gonzalez and colleagues were impressed with the ability of the B-

mode scan to clearly visualize residual plaque after endarterectomy and followed the course of these lesions to resolution or re-stenosis.<sup>43</sup> This group subsequently operated on 16 patients without preoperative endarterectomy.

Crew and colleagues elected to operate without prior arteriography in 65 patients for the variety of reasons presented in Table 2. The duplex ultrasound and continuous wave Doppler spectral analysis impression was confirmed in all cases.<sup>44</sup>

Thomas and colleagues performed 32 carotid endarterectomies in 30 patients without arteriography from 1978 to 1985.<sup>45</sup> The patients were determined to have 75% or greater stenotic lesions by a combination of pulsed Doppler spectral analysis and B-mode imaging (duplex ultrasound). There were several reasons for proceeding without angiography, but one third were "physicians' choice."

Walsh and colleagues operated on 28 patients with amaurosis fugax based on duplex ultrasound identification of lesions.<sup>46</sup> Only 17 of the 28 patients had arteriogram evidence of an ulceration. All had stenosis less than 50%. Walsh and his colleagues concluded that patients who are diagnosed with amaurosis fugax, negative CT scan, and positive findings on B-mode ultrasound can be offered endarterectomy without preoperative angiography.

Moore and colleagues used OPG-GEE and duplex ultrasound to select 29 patients in whom 32 carotid endarterectomies were performed without arteriography.<sup>47</sup> Almost half (14) of the patients were operated on without arteriogram because of surgeons' preference, indicating an increasing confidence in the noninva-

sive techniques. All 32 surgical specimens in the 29 patients correlated with the ultrasound findings.

The largest series of endarterectomies without arteriography to date is that of Hill and colleagues.<sup>48</sup> They initially reported 130 endarterectomies in 101 patients. Duplex ultrasound was the sole diagnostic test for extracranial vascular disease. One patient was denied surgery when an arteriogram confirmed an occlusion identified by ultrasound. The series consisted of two groups of patients: (1) a large university hospital, 39 patients; and (2) a private practice, 62 patients.

The strict criteria proposed by Akers and colleagues were used for patient selection, and interpretations of the sonograms were all done by the senior authors (Figure 6).<sup>37</sup> Surgical specimens correlated with the ultrasound findings in all but one patient. No deaths occurred, and one perioperative stroke was reported in a patient who required a polytetrafluorethylene (PTFE) patch graft.

Hill has extended this series to 347 consecutive cases (personal communication). The indications for surgery were: asymptomatic, 32.4%; TIA/amaurosis fugax, 51.8%; and cerebrovascular accident (CVA), 15.7%. Asymptomatic patients had 75% or greater stenosis, and at least one of the following:

1. Plaque degeneration (hemorrhage) or major plaque ulcers seen on several views
2. Rapidly progressing stenosis with changes in plaque morphology
3. Contralateral ICA occlusion

Perioperative complications in 150 patients before the current "ultrasound alone" approach and in the current group of 347 cases are represented in Table 3. No differences were noted in the perioperative complication rates in both groups. Hill estimated that his approach has realized a savings of close to \$1,735,000 by nearly eliminating the use of arteriography.

Another large series of 130 endarterectomies without angiography in 118 patients was later reported by Cartier and colleagues.<sup>49</sup> Surgeons' preference was the reason for selection of this approach in 62% of the cases. The surgical specimen correlated with the ultrasound finding in 124 (96%) operations. Table 2 summarizes the reports on 438 endarterectomies in 421 patients performed without preoperative arteriography.

Carotid Endarterectomy: Perioperative Complications with Two Different Diagnostic Approaches					
Group	#Patients	Deaths	CVA	TIA	DX Comp
I	150	2 (1.3%)	2 (1.3%)	5 (3.3%)	
II	347	2 (0.6%)	10 (2.9%)	15 (4.3%)	0
CVA	=	cerebrovascular accident			
TIA	=	transit ischemic attack			
Group I	=	arteriography plus duplex ultrasound and surgery			
Group II	=	no arteriography before surgery (see criteria in text)			
The indications for surgery were the same in both groups					

Table 3.



## EXTENDED INDICATIONS FOR ENDARTERECTOMY

The current consensus is that symptomatic patients with a carotid stenosis of greater than 50% are candidates for carotid endarterectomy, and asymptomatic patients with greater than 75% stenosis can be considered.

### Ulcerated Plaque

Some authors believe that tandem lesions and other disorders should not defer endarterectomy because improvement (if not cure) can be anticipated in patients with ulcerated plaque.<sup>36-40</sup> An ulcerated plaque or severe irregularity in a lesion that does not meet the "critical stenosis" test is another indication for carotid endarterectomy, which is gaining more acceptance.<sup>29,33,50</sup> Johnson and colleagues found that ulcers 2 to 4 mm deep were associated with symptoms during one-year follow up in 33% of patients; ulcers greater than 4 mm deep were associated with symptoms in all patients and required surgery at discovery.<sup>33</sup> There seems to be enough evidence to recommend endarterectomy on the basis of finding a large (deep) ulcer or extensive irregularity.

Recent reports show that duplex ultrasound is superior to arteriography parallel, with improvements in duplex ultrasound instruments and increased experience of sonologists. Goodsen and colleagues identified 90% of the ulcers with ultrasound, while arteriography identified only 54% of the ulcers later found in the surgical specimen.<sup>26</sup> O'Donnell and colleagues reported finding 89% of the ulcers with ultrasound, while arteriography identified only 59% of the ulcers found in the surgical specimen.<sup>30</sup> Edwards and colleagues observed that only 60% of ulcers are seen on arteriogram.<sup>31</sup> The characterization of the plaque ulcer has become the province of ultrasound.

### Intra-Plaque Hemorrhage

Hemorrhage into an atheromatous plaque is believed to be the precursor of an atheromatous ulcer. Imperato and colleagues studied 376 plaques removed at surgery and found that plaque hemorrhage was the only gross pathologic feature found more frequently in symptomatic patients than in those free of symptoms.<sup>51</sup> Lusby and colleagues found acute or recent hemorrhage in 92.5% of plaques removed from symptomatic patients, while only 27% of

asymptomatic patients had hemorrhagic plaques.<sup>52</sup> Ammar and colleagues related evidence of repeated hemorrhage in the excised specimen with the production of symptoms.<sup>53</sup> Ultrasound is clearly superior to arteriography in identifying these lesions.

## SUMMARY

It must be understood that the early reports of clinical success in endarterectomy without arteriography reviewed here are from the practices of careful and competent surgeons. They are reporting their encouraging results for general consideration. The low morbidity could be due to their care in patient selection, diligence in interpretation of the sonogram (many were performed by or under direct supervision of the operating surgeon), or their competence in surgery. Of course, if one operates only on high-grade stenosis, correlation with the pathologic specimen is likely. The real strength of their recommendations is in the excellent surgical correlations with the two lesions that may be found in association with stenosis less than 50% and may cause symptoms, but are not readily appreciated by arteriography: atheromatous ulcers and intra-plaque hemorrhage. Duplex Doppler ultrasound holds out the promise of accurately identifying these lesions so surgery may be offered to patients with atherosclerotic ulcers and hemorrhagic plaques. The need to rule out other sources of emboli such as cardiac, and to rule out other intra-cranial sources of symptoms such as tumor or aneurysm, is no different in this setting than in the traditional approach using arteriogram guidance.

To avoid the usual disenchantment that often follows the enthusiastic introduction of a new therapeutic approach, close attention must be paid to the selection protocol as outlined above and in Figure 6. Three basic recommendations are also important:

1. The surgeon should become expert in the duplex ultrasound study and participate in the investigation because this technique is highly operator-dependent and is still in developmental evolution.
2. Tandem lesions should be identified by transcranial Doppler (intra-cranial lesions) or careful physical examination and Doppler spectral analysis of proximal arteries (intra-thoracic lesions).

3. Careful attention must be paid to the patient with a very high-grade stenosis (95%+) as outlined above.

In 1988, we discussed the prospect of replacing arteriography with duplex ultrasound scanning and concluded that the idea was probably premature.<sup>19</sup> The arteriogram will not be replaced, but enough validation and clinical evidence exists currently to indicate that carotid endarterectomy can be performed with confidence on the basis of noninvasive vascular evaluation without supplemental arteriography in a majority of cases where surgery is indicated. **STI**

## REFERENCES

1. Dos Santos R, Lanias AC, Caldo JP. Arteriographie des membres et de l'aorte abdominale. Massonet Cie, Paris, 1931:192.
2. Hass WK, Fields WS, North RR, et al. Joint study of extracranial arterial occlusion. II. Arteriography, techniques, sites and complications. JAMA 1968; 203(11):961-8.
3. Fraught E, Trader SD, Hanna GR. Cerebral complications of angiography for transient ischemia and stroke: Prediction of risk. Neurology 1979; 29:4-15.
4. Gee WG. Ocular pneumoplethysmography: Diagnostic and surgical techniques. Survey Ophthalmol 1985; 29:276-92.
5. Gee W, Masar MF, Dooehen DJ. Calibrated plethysmography in arterial disease. Surg Gynecol Obstet 1971; 133:597-602.
6. Karchner MM, McRae JP, Morrison FD. Noninvasive detection and evaluation of carotid occlusive disease. Arch Surg 1973; 106:528-35.
7. McDonald KM, Gee W, Kaupp HA, et al. Screening for significant carotid stenosis by ocular pneumoplethysmography. Am J Surg 1979; 137(2):244-9.
8. Blackshear W. Comparative review of OPG-KM, OPG-G and pulsed Doppler ultrasound for carotid evaluation. Vasc Diag Ther 1980; October/November, 43-51.
9. Ginsberg MD, Greenwood SA, Goldberg HI. Non-invasive diagnosis of extracranial cerebrovascular disease-oculoplethysmography-phonoangiography and directional Doppler ultrasonography. Neurology 1979; 29:623-31.
10. Strandness DEJ, Ward KS, Phillips DJ, et al. Evaluation of carotid disease by several noninvasive methods. Stroke 1978; 9:106 (Abstract).
11. Bone GE, Barnes TW. Clinical implications of the Doppler cerebrovascular examination: A correlation with angiography. Stroke 1976; 7(3):271-4.
12. Barnes RW, Russell HE, Bone GE, et al. Doppler cerebrovascular examination: Improved results with refinements in technique. Stroke 1977; 8(4):468-71.
13. Kirkham FJ, Neville BGR, Levin SD. Bedside diagnosis of stenosis of the middle cerebral artery. Lancet 1986; 1:797 (Letter).
14. Niederkorn K, Neumayer K. Transcranial Doppler sonography: A new approach in the



- noninvasive diagnosis of intra-cranial brain artery disease. *Eur Neurol* 1987; 26:65-8.
15. Felix WR Jr, Sigel B, Gilson RJ, et al. Pulsed Doppler ultrasound detection of flow disturbances in arteriosclerosis. *J Clin Ultrasound* 1976; 4(4):275-82.
16. Strandness DE Jr. Extracranial arterial disease. In: Strandness DE Jr, ed. *Duplex Scanning in Vascular Disorders*. New York, NY: Raven Press, 1990:62-120.
17. Edelman RR, Waroch S. Magnetic resonance imaging. *NEJM* 1993; 328(10):708-16,785-91.
18. Naylor GL, Firmin DN, Longmore DB. Blood flow imaging by cine magnetic resonance. *J Comput Assist Tomogr* 1986; 10:715-22.
19. Felix WR Jr. Duplex ultrasound scanning for carotid artery disease. In: Felix WR, ed. *Noninvasive Diagnosis of Peripheral Vascular Disease*. New York, NY: Raven Press, 1987:107-124.
20. Blackshear WM Jr, Phillips DJ, Chikos PM, et al. Carotid artery velocity pattern in normal and stenotic vessels. *Stroke* 1980; 11(1):67-71.
21. Zierler RE, Strandness DE Jr, Felix WR Jr. Carotid artery disease: Detection by Doppler imaging and sound spectral analysis. In: Felix WR Jr, ed. *Noninvasive Diagnosis of Peripheral Vascular Disease*. New York, NY: Raven Press, 1989:69-94.
22. Nichols SC, Phillips DJ, Primozich JF, et al. Diagnostic significance of flow separation in the carotid bulb. *Stroke* 1988; 20(2):175-82.
23. Moneta GL, Edwards JM, Chitwood RW. Correlation of North American symptomatic carotid endarterectomy trial (NASCET) angiographic definition of 60% to 99% internal carotid artery stenosis with duplex scanning. *J Vasc Surg* 1993; 17(1):152-9.
24. Barnes CC, Weingarten MS, Czeredarczyk M, et al. Examination of carotid arteries with quantitative color Doppler flow imaging. *J Ultrasound Med* 1994; 13:121-7.
25. Faught WE, Mattos MA, VonBemmelen PS, et al. Color-flow duplex scanning of carotid arteries; new velocity criteria based on receiver operator characteristic analysis for threshold stenoses used in the symptomatic and asymptomatic carotid trials. *J Vasc Surg* 1994; 19(5):818-28.
26. Goodsen SF, Flanigan DP, Bishara RA, et al. Can carotid duplex scanning supplant arteriography in patients with focal carotid territory symptoms? *J Vasc Surg* 1987; 5:551-7.
27. Geuder JW, Lamparello PJ, Riles TS, et al. Is duplex scanning sufficient evaluation before carotid endarterectomy? *J Vasc Surg* 1989; 9(2):193-201.
28. Weintraub MI, Lambert D, Rothman AL. Carotid ultrasonography—the new gold standard. Surgical and angiographic correlation. *Angiography* 1985; 36(1):19-22.
29. Moore WS, Hall AD. Ulcerated atheroma of the carotid artery. A cause of transient cerebral ischemia. *Am J Surg* 1968; 116(2):237-42.
30. O'Donnell TFJ, Erdoes L, Mackey WC, et al. Correlation of B-mode ultrasound imaging and arteriography. *Arch Surg* 1985; 120(4):443-9.
31. Edwards JH, Krichell II, Riles T, et al. Angiographically undetected ulceration of the carotid bifurcation as a cause of embolic stroke. *Radiology* 1979; 133:369-73.
32. Senkowsky J, Bell WH, Kerstein MD. Normal angiograms and carotid pathology. *Am Surg* 1990; 56:726-9.
33. Johnson JM, Ansel AL, Morgan S, et al. Ultrasonographic screening for evaluation and follow-up of carotid artery ulceration. A new basis for assessing risk. *Am J Surg* 1983; 146(2):188-93.
34. Reilly LM, Lusby RJ, Hughes L, et al. Carotid plaque histology using real-time ultrasonography clinical and therapeutic implications. *Am J Surg* 1983; 146(2):188-93.
35. Johnson JM, Kennelly MM, Decesare D, et al. Natural history of asymptomatic carotid plaque. *Arch Surg* 1985; 120(9):1010-2.
36. O'Holleran LW, Kennelly MM, McClurken M, et al. Natural history of asymptomatic carotid plaque. Five year follow-up study. *Am J Surg* 1987; 154(6):659-62.
37. Akers DL, Bell WH III, Kerstein MD. Does intracranial dye study contribute to evaluation of carotid artery disease? *Am J Surg* 1988; 156:87-90.
38. Roederer GO, Langlois YE, Chan ARW, et al. Is siphon disease important in predicting outcome of carotid endarterectomy? *Arch Surg* 1983; 118:1177-81.
39. Schuler JJ, Flanigan DP, Lin LT, et al. The effect of carotid siphon stenosis on stroke rate, death and relief of symptoms following elective carotid endarterectomy. *Surgery* 1982; 92:1058-67.
40. Moore WS. Does tandem lesion mean tandem risk in patients with carotid artery disease? *J Vasc Surg* 1988; 7(8):454-5.
41. Akers DL, Markowitz IM, Kerstein MD. The value of aortic arch study in the evaluation of cerebrovascular insufficiency. *Am J Surg* 1987; 154:230-2.
42. Blackshear WB, Commar RG. Carotid endarterectomy without angiography. *J Cardiovasc Surg* 1982; 23(6):477-82.
43. Gonzales LL, Pertusch L, Wirth P. Noninvasive carotid artery evaluation following endarterectomy. *J Vasc Surg* 1984; 1(3):403-8.
44. Crew JR, Dean M, Johnson JM, et al. Carotid surgery without angiography. *Am J Surg* 1984; 148(2):217-20.
45. Thomas GI, Jones TW, Stavney LS, et al. Carotid endarterectomy after Doppler ultrasonographic examination without angiography. *Am J Surg* 1986; 151:616-9.
46. Walsh J, Markowitz I, Kerstein MD. Carotid endarterectomy for amaurosis fugax without angiography. *Am J Surg* 1986; 152(2):172-4.
47. Moore WS, Ziomek S, Quinones-Baldrich WS. Can clinical evaluation and noninvasive testing substitute for arteriography in the evaluation of carotid artery disease? *Ann Surg* 1988; 208(1):91-4.
48. Hill JC, Carbonneau K, Baliga PK, et al. Safe extracranial vascular evaluation and surgery without preoperative arteriography. *Am Vasc Surg* 1990; 4(1):34-7.
49. Cartier R, Cartier P, Fontaine A. Carotid endarterectomy without angiography. The reliability of Doppler ultrasonography and duplex scanning in preoperative assessment. *Can J Surg* 1993; 36(5):441-6.
50. Houser OW, Thorale M, Sundi T, et al. Atheromatous disease of the carotid artery. Correlation of angiographic, clinical and surgical findings. *J Neurosurg* 1984; 41(3):321-31.
51. Imperato AM, Riles TS, Mintzer R, et al. The importance of hemorrhage in the relationship between gross morphologic characteristics and cerebral symptoms in 376 carotid artery plaques. *Ann Surg* 1983; 197(2):195-203.
52. Lusby RJ, Ferrell LD, Ehrenfeld WK. Carotid plaque hemorrhage. Its role in production of cerebral ischemia. *Arch Surg* 1982; 117(11):1479-88.
53. Ammar AD, Ernst RL, Lin JJ. The influence of repeated carotid plaque hemorrhage on the production of cerebrovascular symptoms. *J Vasc Surg* 1986; 3(16):857-9.