

Moist Wound Healing: Current Concepts and Applications

WILLIAM BRUNO, B.A.

MEDICAL STUDENT, HAHNEMANN UNIVERSITY SCHOOL OF MEDICINE,
PHILADELPHIA, PA

MORRIS D. KERSTEIN, M.D.

DEISSLER PROFESSOR IN SURGERY,
HAHNEMANN UNIVERSITY SCHOOL OF MEDICINE,
PHILADELPHIA, PA

The search for the optimal environment that enhances tissue healing is well under way. Since Winter's landmark study over 30 years ago,¹ moist wound healing has become the subject of intensive scientific and clinical research. Numerous studies of molecular and cell biology have demonstrated the benefits of wound healing in a moist environment. The use of occlusive dressings that retain moisture is now accepted as a first line of treatment in the management of a variety of wound types. Clinicians have a myriad of dressing alternatives at their disposal that enable more active control over the healing process. This article reviews the beneficial effects of moist wound healing and the occlusive dressings available to achieve such an environment.

FIBRINOLYSIS

For healing to occur in a wound, fibrin must be removed from the inflamed tissue. Especially in chronic venous ulcers, the formation of "fibrin cuffs" is believed to inhibit tissue repair by preventing growth factors, oxygen, and nutrients from reaching the wound.² Under an occlusive dressing, however, the wound fluid has been shown to contain metalloproteinases that enhance fib-

rin clot and eschar dissolution.³ Furthermore, this study showed that wound fluid from occluded wounds stimulates urokinase production by fibroblasts *in vitro*. Another recent study has demonstrated that a hydrocolloid dressing is able to reduce the number of pericapillary fibrin cuffs when compared with the same compression plus the boot (Unna).⁴ Neutrophils and endothelial cells produce plasminogen activator that breaks down fibrin more efficiently in a moist environ-

ment. The fibrinolytic effect of some occlusive dressings may promote increased perfusion of the wound and, subsequently, shorter healing times.

ANGIOGENESIS

Increased vascularization of wounds occurs in the moist milieu under occlu-

sive dressings. The reason for this phenomenon is attributed to the relatively hypoxic environment that exists with occlusion.⁵ Studies have shown the optimal growth of fibroblasts in tissue culture occurs at low partial pressures of oxygen and keratinocyte inhibition of growth at ambient oxygen levels.^{5,6} Angiogenesis occurred more rapidly

under moist wound conditions and the vessels displayed an earlier entry into the remodelling phase (Figures 1 and 2).^{7,8} A greater degree of vascular "maturity" and larger-diameter vessels were also noted in moist wounds. Factors such as heparin⁹ and tumor necrosis factor-alpha (TNF-alpha)¹⁰ that exist under occlusive dressings may also contribute toward increased angiogenesis. Opportunity for wound infections is consequently lowered by the increased tissue perfusion occurring under occlusive dressings.

INFECTION AND OCCLUSIVE DRESSINGS

Before discussing a relationship with moisture-retentive dressings, a distinction must first be made between colonization (contamination) and infection. Colonization implies the mere presence of microorganisms. To diagnose infection requires several clinical signs such as heat, erythema, localized pain, edema, and cellulitis in addition to a bacterial count greater than 10^5 colony forming units per gram of tissue.¹¹ The presence of bacteria does not imply invasion of tissues, therefore, presence of microorganisms is only indicative, not diagnostic, of infection.¹²

Another issue that needs to be addressed is that of occlusive dressings potentiating the risk of infection. Total occlusion can cause the normal skin and wound flora to proliferate, however, endogenous infection is not increased under these conditions. In fact, overall infection rates of occlusive dressings compared to non-occlusive dressings were significantly lower (2.6% for occlusive, 7.1% for non-occlusive).¹³ Occlusive dressings were associated with lower rates of infection for all wound types examined,¹² possibly because phagocytic cell viability is increased at the moist wound surface.^{14,15} Hydrocolloid dressings, in particular, create an acidic environment that may be antibacterial.⁵

Exogenous infections are also prevented by the use of occlusive dressings. Hydrocolloid dressings have been used to prevent the spread of methicillin-resistant *Staphylococcus aureus* in hospitalized patients.¹⁶ Of equal importance is the role of hydrocolloid dressings in reducing airborne dispersal of bacteria during redressing. The number of bacteria released into the air from conventional (gauze) dressings was found to be considerably higher than that of the hydrocolloid dressing DuoDERM® (ConvaTec, Skillman, NJ).¹⁷

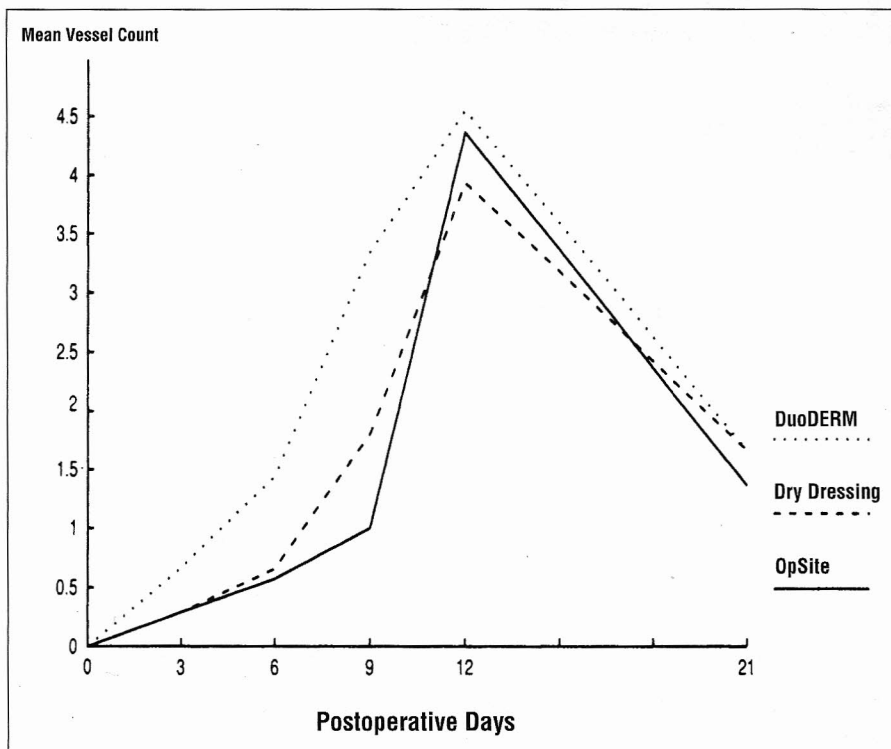


Figure 1. Angiogenic response in porcine full-thickness wounds covered with DuoDERM®, OpSite®, or dry dressing and assessed by immuno-fluorescence. (With permission from Pickworth JJ, de Sousa N. Angiogenesis and macrophage response under the influence of DuoDERM®. In: Cederhoom-Williams SA, Ryan TJ, Lydon MJ, eds. Fibrinolysis and Angiogenesis in Wound Healing. Highlights of the 2nd International Forum; December 4, 1987; San Antonio, TX, Princeton NJ: Excerpta Medica/An Elsevier Company; 1988:44-8.)

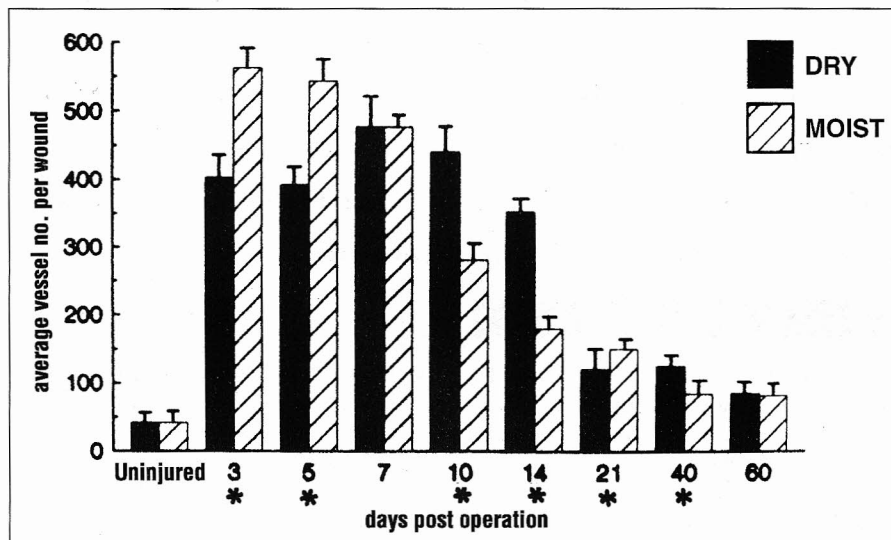


Figure 2. Bar chart showing average vessel number (\pm standard deviation) per wound against days post operation. Vessel counts carried out in zone 1. $p < 0.05$. (Reprinted by permission of Elsevier Science Inc. from Dyson M. Young SR, Hart J, et al. Comparison of the effects of moist and dry conditions on the process of angiogenesis during dermal repair. *J Invest Dermatol* 1992; 99:729-33.)

GROWTH FACTORS AND MOIST WOUND HEALING

A variety of growth factors are involved in the dynamics of wound healing. Occlusive dressings provide the environment necessary for the survival of cells responsible for liberating these biochemical modulators. As a wound occurs, platelet-derived growth factor (PDGF) and transforming growth factor-beta (TGF-beta) are released to stimulate fibroblast proliferation. Fibroblasts produce collagen that functions as the essential component of granulation tissue. Macrophages also secrete growth factors such as epidermal growth factor (EGF), fibroblast growth factor (FGF), and interleukin (IL-1). These growth factors participate in the process of angiogenesis and development of the stratum corneum.¹⁸ Several studies have demonstrated growth factors in the fluid under occlusive dressings that stimulate *in vitro* fibroblast, endothelial cell, and keratinocyte proliferation.^{3,19,20} Under current investigation is the possibility of components of hydrocolloid dressings interacting with wound fluid to further modify the healing process.³ Therapeutic approaches involving topical applications of exogenous growth factors are also being explored.^{21,22}

CELL-CELL INTERACTIONS UNDER OCCLUSION

Numerous cell-cell interactions that occur during the healing process are augmented under occlusive dressings. Normally, neutrophils invade wounds early and are followed several days later by macrophages, monocytes, and T-lymphocytes. In a quantitative study comparing moist and dry wound conditions, an acceleration of the inflammatory phase of repair was noted in the moist wounds by observing 50% fewer neutrophils and 90% more macrophages three days after injury (Figure 3).²³ Significantly more fibroblasts were measured in the moist than the dry wounds three days after injury, further suggesting an accelerated rate of healing under occlusion.²³ Fibroblasts and endothelial cells in the granulation tissue of moist wounds displayed an arrangement typical of contractile myofibroblasts,^{23,24} which may account for the increased contraction noted in moist wounds.

Adhesive interactions between leukocytes and the vascular endothelium are mediated by lymphocyte-func-

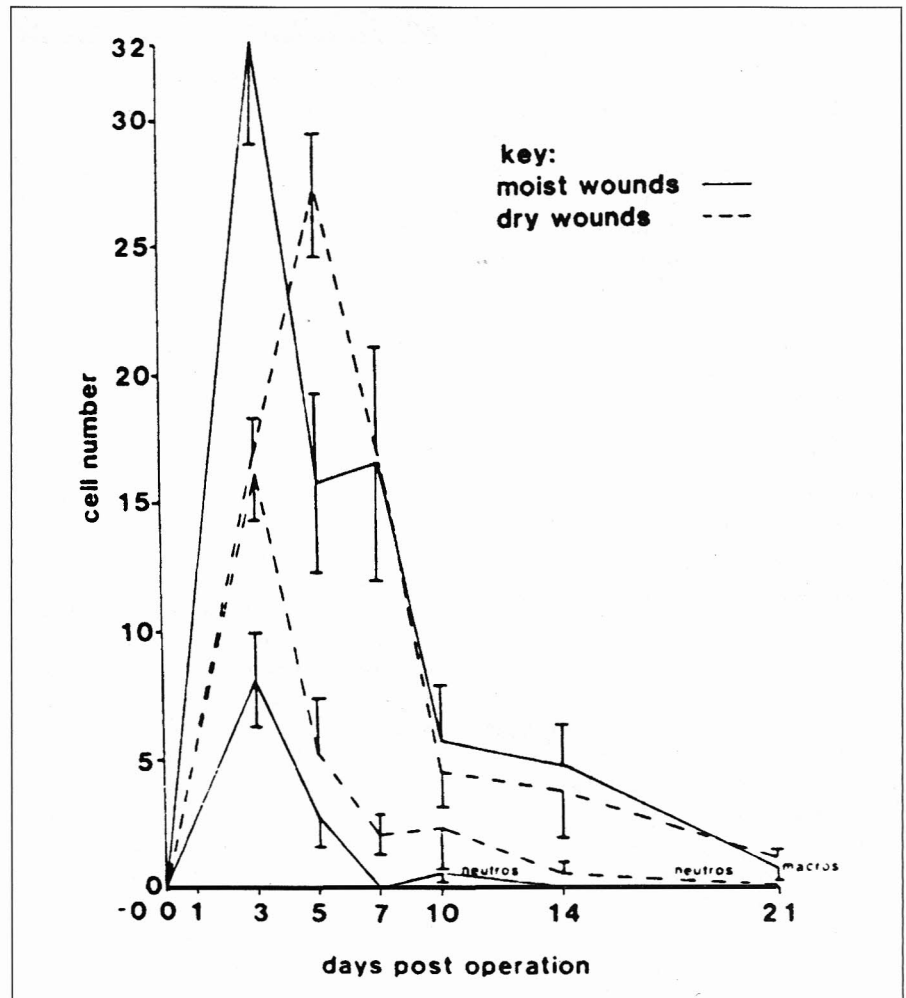


Figure 3. Graft plotting number of inflammatory cell (neutrophils and macrophages) per unit area against days after surgery. (Reprinted by permission of Elsevier Science Inc. from Dyson M, Young S, Pendle CL, et al. Comparison of the effects of moist and dry conditions on dermal repair. *J Invest Dermatol* 1988;

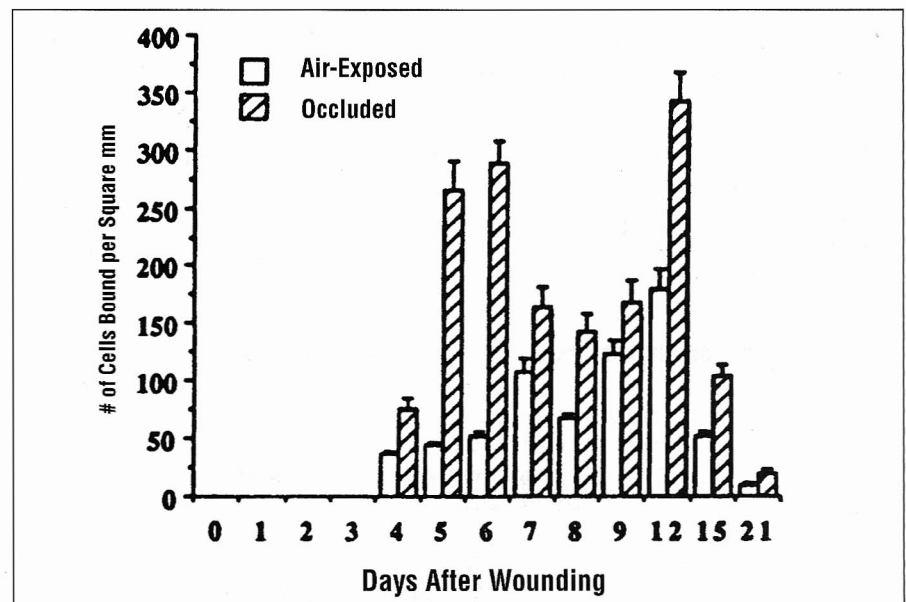


Figure 4. Kinetic of porcine peripheral blood mononuclear cell adherence to air-exposed and occluded wound biopsies from day 0 to day 21 after wounding. Porcine peripheral blood mononuclear cells were overlaid onto frozen sections of air-exposed or occluded wounds and the binding quantitated. The results represented means and SE of three separate experiments. (Reprinted by permission of Elsevier Science Inc. from Harris B, Jian-Ping C, Falanga V, et al. The effects of occlusive dressings on the recruitment of mononuclear cells by endothelial binding into acute wounds. *J Dermatol Surg Oncol* 1992; 18:279-83.)

tion-associated antigen (LFA-1) and intracellular adhesion molecule (ICAM-1), respectively.²⁵ These interactions help determine the rate of inflammation and granulation tissue formation. Wounds covered with occlusive dressings showed an increased number of monocytes and lymphocytes adhering to the wound site one day earlier than air-exposed wounds (Figure 4).²⁶ Although occlusion was not able to shorten the time at which cell adhesion began to occur, it may have enhanced the effectiveness of mononuclear cell adhesion to the microvascular endothelium. This could, in turn, augment the mononuclear cell migration into wounds, thus improving healing rates.²⁶

APPLICATIONS OF MOIST WOUND HEALING

Many dressing materials are available for the treatment of a wide range of wound types. The clinician is faced with the dilemma of choosing the appropriate dressing for a specific wound. Because no established standards exist, most clinicians rely upon tradition or institutional protocol to guide their selection process regarding wound dressing. Clinicians must approach wound healing and its treatment as they would any medical or surgical condition. Proper diagnosis of the individual wound type, understanding of the pathophysiology, and deciding upon the best course of management are essential for optimal wound healing. The currently available occlusive (moisture-retentive) dressings are reviewed, with an emphasis on the hydrocolloid dressings, which have recently been shown to be superior to most forms of occlusion. In addition, several of the newer dressing alternatives are outlined to shed further light on the now complex issue of wound dressing.

CATEGORIES OF OCCLUSIVE DRESSINGS

Occlusive dressings appear to be the best means of providing an ideal wound-healing environment, with optimal use shown when applied within two hours of wounding.²⁷ Additionally, these dressings provide a barrier against exogenous infection, prevent trauma, and reduce scarring and wound pain. The delivery of topical medications and autolytic debridement are also facilitated by moisture-retentive dressings. These dressings are categorized based upon their physical composition. The major groups of occlusive dressings include: films, hydrogels, wound-filler products, composite polymers, and hydrocolloids.

The polyurethane and polyethylene film dressings (eg, Bioclusive[®] [Johnson & Johnson, New Brunswick, NJ], OpSite[®] [Smith & Nephew, London, England]) are typically transparent, waterproof dressings used in a variety of wound situations. Superficial abrasions, skin-graft donor sites, minor burns, and intravenous sites are among their common uses. These films may be better suited for long-term applications.²⁸ Removal of such dressings must be carefully performed to avoid damaging the new wound surface epithelium.²⁹ Film dressings are prone to leakage of exudate, which subsequently requires the use of another dressing (gauze) to preserve the wound's integrity.

Hydrogel dressing (eg, Elasto Gel[®] [Southwest Technologies, Houston, TX], Cutinova[®] [Beiersdorf, Munich, Germany]) are made of cross-linked polymers such as polyethylene oxide and polyvinyl-pyrrolidone. Water comprises the vast majority of the composition of the hydrogels and contributes to the cooling effects that can reduce pain.³⁰ Hydrogels are used in the treatment of burns (second-degree), blisters, skin-graft donor sites, and some pressure ulcers.

These dressings must be kept moist, which poses management difficulties for clinicians as well as for outpatient use.

The function of wound-filler products (absorptive dressings) is to absorb exudate in heavily draining chronic wounds. These dressings are available in a variety of forms such as gels, beads, powders, and pastes. Examples include Debrisan[®] beads (Johnson & Johnson, New Brunswick, NJ), Comfeel[®] paste (Coloplast, St. Louis, MO), and Spand-Gel[®] (Medi-Tech, Boston, MA). Cost, availability, and application may contribute to their limited use.

Composite polymeric dressings such as BioBrane[®] (Winthrop, Mt. Laurel, NJ) and Synthaderm[®] (Calgon-Vestal, St. Louis, MO) are made of different layers performing different functions. A hygroscopic layer, designed to absorb exudate, is coupled with an occlusive layer for maintenance of a moist wound environment. This combination allows for a diverse range of clinical usage including pressure ulcers, partial-thickness wounds, graft sites, donor sites, and burns.

Perhaps the most studied of the occlusive dressings are the hydrocolloids (eg, DuoDERM[®] [ConvaTec, Skillman, NJ], Tegaderm[®] [3M, St. Paul, MN]). These bilaminate membranes have an inner hydrocolloid layer that contains hydrophilic particles, such as gelatin or pectin, combined with a hydrophobic adhesive matrix that absorbs exudate to form a hydrated gel over the wound. The outer layer is a polyurethane foam or film sheet impermeable to gases, water vapor, and fluids. This outer layer forms a barrier to protect the wound from bacterial contamination and foreign debris (urine, feces, etc.). These dressings are appropriate for moderately draining wounds, skin-graft donor sites, burns (second-degree), and pressure ulcers.

Hydrocolloid dressings fulfill many of the criteria for the optimum dressing. Such criteria as outlined by Turner and others include: the maintenance of a moist wound environment, removal of excess exudate, thermal insulation, impermeability to bacteria, and atraumatic removal (Table 1).^{12,14,31,32} Hydrocolloids are designed to remain in place for one week, thus requiring less redressing and avoiding its associated pain. These dressings adhere to both dry and moist skin surfaces, but do not damage newly formed epithelium upon removal. Patient compliance is high with hydrocolloid dressings because frequent dressing changes are unnecessary, no secondary

Some characteristics of the "ideal" wound healing

- Handling of excess exudate
- Removal of toxic substances
- Maintenance of moist environment over the wound
- Permit gaseous exchange
- Present a barrier to microorganisms
- Provide thermal insulation
- Demonstrate freedom from particulate contaminants
- Removal without trauma to new tissue

Table 1. (Reprinted by permission of Academic Press Limited, from Hutchinson JJ, Lawrence JC. Wound infection under occlusive dressings. *J Hosp Infect* 17:83-94, 1991. Adapted from Lawrence JC. What materials for dressing? *Injury* 1982; 13:500-12. Turner TD. Current and future trends in wound management. *I: Wound healing and traditional surgical dressings. Pharm Inter* 1985; May:117-9.)

dressings are involved, and the waterproof feature allows for easy bathing. Furthermore, due to their conformability, hydrocolloids can be used in a number of awkwardly located wound sites, such as elbows, fingers, and heels. The ideal situation for use of a hydrocolloid dressing involves an inpatient or outpatient with a chronic wound or donor site draining low-to-moderate amounts of exudate.

Such partial-thickness wounds responded favorably to hydrocolloids when compared to other dressings (Figure 5).³³ One recent study examined the healing rates of skin-graft donor sites dressed with hydrocolloids versus those dressed conventionally (impregnated gauze) (Figure 6).³⁴ Overall healing rates were significantly faster and fewer infections developed with the hydrocolloid dressings. Another clinical trial compared DuoDERM® (hydrocolloid dressing), BioBrane® (temporary wound dressing), and Xeroform® (a conventional gauze) on skin-graft donor sites.³⁵ DuoDERM® was rated the most comfortable overall and found to be ideal for smaller donor sites. Hydrocolloids also had a shorter complete healing time when compared with alginate dressings on skin-graft donor sites.³⁶

In addition to skin-graft donor sites, hydrocolloid dressings have been effective in a number of other wound situations. Chronic venous ulcers³⁷⁻³⁹ and diabetic (neuropathic) ulcers⁴⁰ are reported to heal favorably under hydrocolloid dressings. Burn wounds also benefit from hydrocolloid dressings, in particular, superficial burns.¹³ The reduction in pain and waterproof features associated with hydrocolloid dressings makes them especially useful in pediatric wounds.⁴⁰ These dressings have a role in the treatment of pressure sores, but are not used for deep sores such as sacral decubiti.⁴¹

Although the hydrocolloid dressings have proved to be effective in diverse wound settings, they have several limitations and disadvantages that must be discussed. Excessive wound drainage is poorly managed by hydrocolloid dressings, creating a problem of leakage for outpatients. It has been reported that hydrocolloids may leave residual dressing particles in the wound that can cause chronic granulomatous inflammatory reactions.⁴² Hydrocolloid dressings are not well-suited for acute, full-thickness wounds, especially if tendon or bone is visible. If changed too early, these dressings may be difficult to remove because

they are designed to remain in place for one week. Widespread acceptance of hydrocolloid dressings may be deterred due to their high associated cost.

NEW OCCLUSIVE DRESSING ALTERNATIVES

Among the new occlusive dressing alternatives, the alginate dressings appear to be most promising (Tables 2 and 3).⁴³ Several types of kelp and algae are used in the production of these complex polysaccharides derived from "salts" of alginic acid. Calcium alginate dressings are transformed into a biodegradable, non-toxic hydrophilic gel at the

wound surface by way of an ion exchange reaction between the calcium in the alginate and sodium in the wound exudate.³⁶ The release of calcium from the alginate dressing accounts for its unique hemostatic property by providing free calcium ions for the clotting cascade. This quality of the alginates makes them an excellent postoperative dressing choice.⁴³ However, the common use of alginate dressings is in the management of decubiti and ulcers.⁴⁴ Regardless of the cause of the wound, alginate dressings are only indicated for exudative wounds because, if allowed to dry, alginates may adhere to the wound.

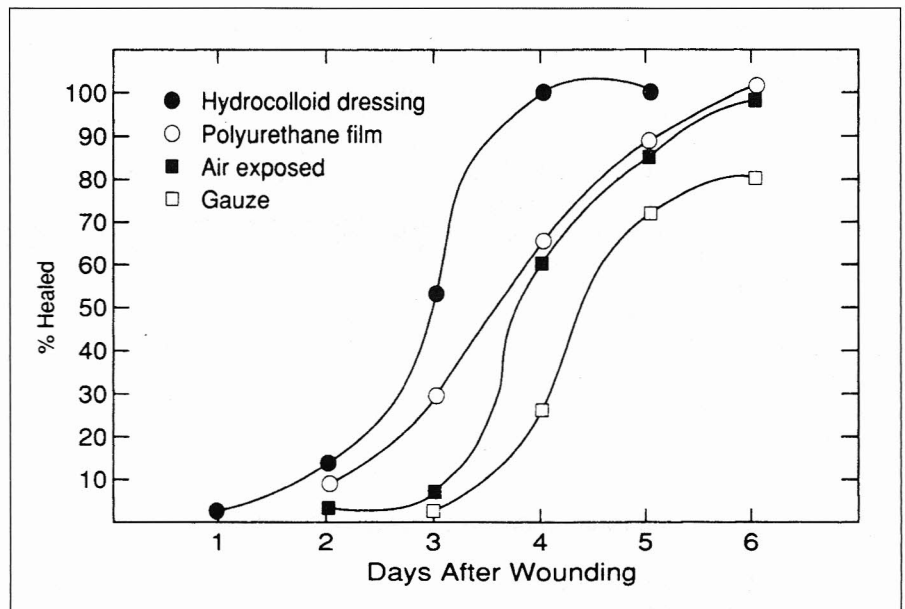


Figure 5. Epithelial resurfacing under various wound dressings. (Reprinted with permission of Journal of Surgical Research from Alvarez OM, Mertz PM, Eaglstein WH. The effect of occlusive dressings on collagen synthesis and reepithelialization in superficial wounds. *J Surg Res* 1983; 35:142-8.)

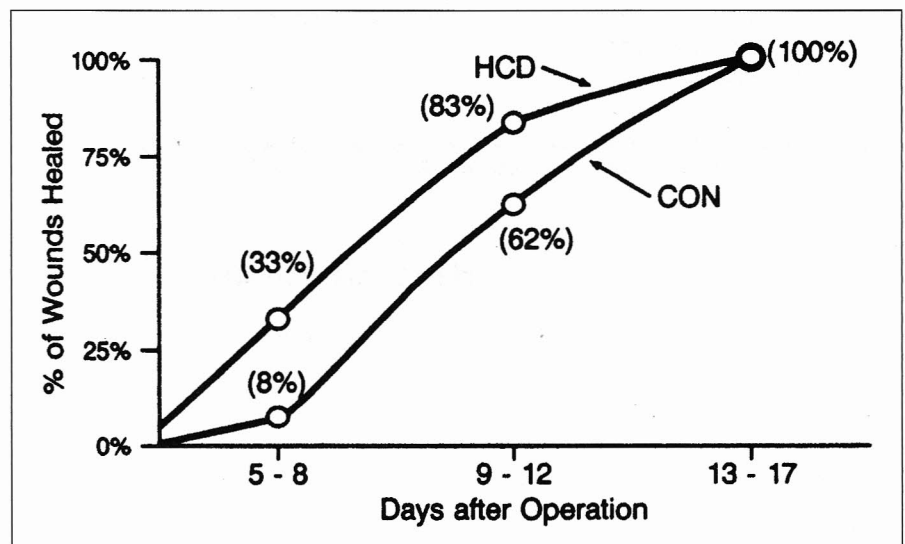


Figure 6. Healing rates of skin-graft donor sites treated with hydrocolloid (HCD) or conventional (CON) dressings. (Reprinted with permission of Plastic and Reconstructive Surgery from Smith DJ, Thomson PD, Bolton LL, et al. Microbiology and healing of the occluded skin-graft donor site. *Plast Reconstr Surg* 1993; 91:1094-7.)

Combination dressings composed of alginates and hydrocolloids need to be further investigated.

Several other new dressing alternatives deserve mention. These dressings emphasize wound healing in a moist environment while improving upon some of the shortcomings of the hydrocolloids. For instance, dressings with the ability to respond to a wound's exudate level by automatically adjusting its moisture vapor transmission rate (MVTR) are currently being developed.⁴⁵ Such so-called "intelligent" dressings could then maintain a constant level of hydration at the wound surface. A polyurethane film has been developed that has no adhesive over the area corresponding to the wound site, thus eliminating the problem of damaged granulation tissue that occurs upon removal of the conventional film dressings. Dressings with high MVTRs, which allow more moisture to escape the wound surface, can be layered upon a wound, affording the clinician a degree of control over the exudate level. The previously mentioned hydrogels, composite polymers, and alginates are also among the new dressing alternatives being incorporated into moist wound management.

CONCLUSION

Clinicians must appreciate the importance and complexity of the different wound types and the wound-healing process. To benefit from the wealth of information derived from experimental and clinical research, an understanding of individual wound requirements is essential. Consideration and selection of appropriate dressing alternatives may then proceed accordingly. Occlusive dressings allow the clinician to exhibit a measure of control over the wound-healing environment and, consequently, the wound-healing process. Such an approach can shorten wound-healing times as well as patient hospital stays. All patients, regardless of their illness, can ultimately reap the benefits of moist wound healing under occlusive dressings. **STI**

REFERENCES

1. Winter GD. Formation of the scab and the rate of epithelialization of superficial wounds in the skin of the young domestic pig. *Nature* 1962; 193:293-4.
2. Falanga V, Eaglstein WH. The "trap" hypothesis of venous ulceration. *Lancet* 1993; 341:1006-7.

3. Chen WY, Rogers AA, Lydon MJ. Characterization of biologic properties of wound fluid collected during early stages of wound healing. *J Invest Dermatol* 1992; 99:559-64.
4. Mulder G, Jones R, Cherry G, et al. Fibrin cuff lysis in chronic venous ulcers treated with a hydrocolloid dressing. *J Invest Dermatol* 1993; 32:304-6.
5. Varghese MC, Balin AK, Carter M, et al. Local environment of chronic wounds under synthetic dressings. *Arch Dermatol* 1986; 122:52-7.
6. Horikoshi T, Balin AK, Elsinger M, et al. Modulation of proliferation in human epidermal keratinocyte and melanocyte cultures by dissolved oxygen. *Invest Dermatol* 1984; 82:411 (Abstract).
7. Pickworth JJ, de Sousa N. Angiogenesis and macrophage response under the influence of DuoDERM®. In: Cederhorm-Williams SA, Ryan TJ, Lydon MJ, eds. *Fibrinolysis and Angiogenesis in Wound Healing. Highlights of the 2nd International Forum*; December 4, 1987; San Antonio, TX, Princeton NJ: Excerpta Medica/An Elsevier Company; 1988:44-8.
8. Dyson M, Young SR, Hart J, et al. Comparison of the effects of moist and dry conditions on the process of angiogenesis during dermal repair. *J Invest Dermatol* 1992; 99:729-33.
9. Folkmann J, Klagsbrun M. Angiogenic factors. *Science* 1987; 235:442-7.
10. Leibovich SJ, Polverini PJ, Shepard HM, et al. Macrophage-induced angiogenesis is mediated by tumor necrosis factor alpha. *Nature* 1987; 329:630-2.
11. Pruitt BA. The diagnosis and treatment of infection in the burned patient. *Burns* 1984; 11:79-81.
12. Hutchinson JJ, Lawrence JC. Wound infection under occlusive dressings. *J Hosp Infect* 1991; 17:83-94.
13. Hutchinson JJ, McGuckin M. Occlusive dressings: A microbiologic and clinical review. *Am J Infect Control* 1990; 18:257-68.
14. Lawrence JC. What materials for dressing? *Injury* 1982; 13:500-12.
15. Witkowski JA, Parish LC. Cutaneous ulcer therapy. *Int J Dermatol* 1986; 25:420-6.
16. Dunn LJ, Wilson P. Evaluating the permeability of hydrocolloid dressings to multi-resistant *Staphylococcus aureus*. *Pharm J* 1990; 248:50.
17. Lawrence JC. Dressings and wound infection. *Am J Surg* 1994; 167(Suppl 1A):21-4.
18. Bolton I, Pirone L, Chen J, et al. Dressings' effects on wound healing. *Wounds* 1990; 2:126-34.
19. Madden MR, Nolan E, Finkelstein JL, et al. Comparison of an occlusive and semi-occlusive dressing and the effect of wound exudate upon keratinocyte proliferation. *J Trauma* 1989; 29:924-31.
20. Katz MH, Alvarez AF, Kirsner RS, et al. Human wound fluid from acute wounds stimulates fibroblast and endothelial cell growth. *J Am Acad Dermatol* 1991; 25:1054-8.
21. Brown GL, Nanney LB, Griffen J, et al. Enhancement of wound healing by topical treatment with epidermal growth factor. *N Engl J Med* 1989; 321:76-9.

Characteristics of alginate dressings

- Absorbent gel-forming alginic salt
- Soluble gel is nonadherent
- Appropriate for exudative wounds or surgical sites
- Maintains moist wound healing environment
- Hemostatic (calcium salt)
- Dressing changes aided by ability to irrigate away old dressing with saline
- Reduces wound pain
- Conforms easily to wound bed

Table 2. (Reprinted with permission of Elsevier Science Publishers BV from Placquadro D, Nelson DB. Alginates—A new dressing alternative. *J Dermatol Surg Oncol* 1992; 18:992-5.)

Properties of classes of biosynthetic dressings

Characteristic	Films	Hydrocolloids	Hydrogels	Alginates
Transmits oxygen	+	-	+(?)	+(?)
Transmits moisture	+	-	-(?)	+
Excludes bacteria	±	+	-	-
Absorbs fluid	-	+	±	++
Transparent	+	-	±	-
Adhesive	+	+	-	-
Wound pain reduction	+	+	+	+

Table 3. (Reprinted with permission of Elsevier Science Publishers BV from Placquadro D, Nelson DB. Alginates—A new dressing alternative. *J Dermatol Surg Oncol* 1992; 18:992-5.)

22. McKay IA, Leigh IM. Epidermal cytokines and their roles in cutaneous wound healing. *Br J Dermatol* 1990; 124:513-8.
23. Dyson M, Young S, Pendle CL, et al. Comparison of the effects of moist and dry conditions on dermal repair. *J Invest Dermatol* 1988; 91:434-9.
24. Majno G. The story of the myofibroblasts. *Am Surg Pathol* 1979; 3:535-42.
25. Haskard D, Cavender D, Beatty P, et al. T lymphocyte adhesion to endothelial cells: mechanisms demonstrated by anti-LFA-1 monoclonal antibodies. *J Immunol* 1986; 137:2901-6.
26. Harris B, Jian-Ping C, Falanga V, et al. The effects of occlusive dressings on the recruitment of mononuclear cells by endothelial binding into acute wounds. *J Dermatol Surg Oncol* 1992; 18:279-83.
27. Eaglstein WH, Davis SC, Mehle AL, et al. Optimal use of an occlusive dressing to enhance healing. *Arch Dermatol* 1988; 124:392-5.
28. Berardesca E, Vignoli GP, Fidel D, et al. Effect of occlusive dressings on the stratum corneum water holding capacity. *Am J Med Sci* 1992; 304:25-8.
29. James SH, Watson CE. The use of OpSite®, a vapour permeable dressing on skin graft donor sites. *Br J Plast Surg* 1978; 28:107.
30. Yates DW, Hadfield JM. Clinical experience with a new hydrogel wound dressing. *Injury* 1984; 16:23-4.
31. Turner TD. Which dressing and why? *Nurs Times* 1982; 78(Suppl):1-3.
32. Turner TD. Current and future trends in wound management. I: Wound healing and traditional surgical dressings. *Pharm Inter* 1985; May:117-9.
33. Alvarez OM, Mertz PM, Eaglstein WH. The effect of occlusive dressings on collagen synthesis and reepithelialization in superficial wounds. *J Surg Res* 1983; 35:142-8.
34. Smith DJ, Thomson PD, Bolton LL, et al. Microbiology and healing of the occluded skin-graft donor site. *Plast Reconstr Surg* 1993; 91:1094-7.
35. Feldman DL, Rogers A, Karpinski RH. A prospective trial comparing BioBrane®, DuoDERM® and Xeroform® for skin graft donor sites. *Surg Gynecol Obstet* 1991; 173:1-5.
36. Porter JM. A comparative investigation of re-epithelialization of split skin graft donor areas after application of hydrocolloid and alginate dressings. *Br J Plast Surg* 1991; 44:333-7.
37. Mofatt CJ, Franks PI, Oldroyd M, et al. Randomized trial of an occlusive dressing in the treatment of chronic non-healing leg ulcers. *Phlebology* 1992; 7:105-7.
38. van Rijswijk L, Brown D, Friedman S, et al. Multicenter clinical evaluation of a hydrocolloid dressing for leg ulcers. *Cutis* 1985; 35:173-6.
39. Teepe GC, Roseeuw DI, Hermans J, et al. Randomized trial comparing cryopreserved cultured allografts with hydrocolloid dressings in healing chronic venous ulcers. *J Am Acad Dermatol* 1993; 29:982-8.
40. Rasmussen H, Hojer Larsen MJ, Skeie E. Surgical wound dressing in outpatient paediatric surgery. *Dan Med Bull* 1993; 40:252-4.
41. Mumford JW, Mumford SP. Occlusive hydrocolloid dressing applied to chronic neuropathic ulcers. *Int J Dermatol* 1988; 27:190-2.
42. Dealey C. Role of hydrocolloids in wound management. *Br J Nurs* 1993; 2:358-65.
43. Placquadro D, Nelson DB. Alginates—a “new” dressing alternative. *J Dermatol Surg Oncol* 1992; 18:992-5.
44. Leek MD, Barlow YM. Tissue reactions induced by hydrocolloid wound dressings. *J Anat* 1992; 180(Part 3):545-51.
45. Palamand S, Reed AM, Weimann LJ. Testing intelligent wound dressing. *Biomater Appl* 1992; 6:198-215.