

Innovative Techniques in Lower Extremity Revascularization

JOCK R. WHEELER, M.D., F.A.C.S.
PROVOST AND DEAN
EASTERN VIRGINIA MEDICAL SCHOOL
NORFOLK, VIRGINIA

CHRISTOPHER S. DICKSON, M.D.
VASCULAR RESEARCH FELLOW
EASTERN VIRGINIA MEDICAL SCHOOL
NORFOLK, VIRGINIA

Revascularization of the ischemic foot remains a significant challenge for even the most experienced vascular surgeons. Lower extremity revascularization can be accomplished by endarterectomy, endovascular techniques, or bypass. In experienced hands, excellent results have been reported with endarterectomy.¹ However, this technique has limited application because of the diffuse nature of infringuinal atherosclerotic disease. Endovascular techniques, such as atherectomy and laser-assisted balloon angioplasty, gained enormous popularity initially because they were less invasive than standard techniques. Unfortunately, the long-term results with these techniques have been disappointing.

The standard for lower extremity revascularization remains infrainguinal bypass. Advances in instrumentation and technique have allowed bypasses to pedal arteries with acceptable patency. Using new endovascular tools, femorotibial bypasses can now be performed through two small incisions. The purpose of this chapter will be to review the many new techniques which have been described for lower extremity revascularization.

ENDOASCULAR TECHNIQUES

Endovascular surgery began in 1963 when Dotter, while trying to obtain an aortogram, serendipitously passed a catheter through an occluded iliac artery.² In 1964, Dotter and Judkins

reported on this technique; however, this report was ignored for a decade.³ In 1974, Grüntzig introduced the polyvinyl balloon catheter, and soon after, angioplasty gained tremendous popularity.⁴ Angioplasty works by fracturing the atherosclerotic plaque and stretching the media and adventitia. The major limitation of angioplasty has been restenosis. This is an area of intense basic science research. Nonetheless, for isolated, short-segment iliac lesions, the patency rates of iliac angioplasty are comparable to those of aortofemoral bypass.⁵ The results have not been as good for infringuinal disease. Five-year patency for angioplasty of the femoral or popliteal arteries averages 60%,^{6,7} compared to approximately 70% five-year patency for femoropopliteal bypass.^{8,9} It is diffi-

cult to compare this data, however, because follow-up has been less rigorous after angioplasty. There is little long-term data on angioplasty of the infrapopliteal vessels.

One of the limitations of angioplasty is that a guidewire often cannot be passed through an occluded vessel. This led to the development of laser-assisted balloon angioplasty (LABA), the laser being used to recanalize the obstructed artery in order to create a channel for the guidewire and balloon angioplasty system. Initial results with this technique were encouraging^{10,11}; however, long-term results were poor. In our initial experience with LABA, we treated 56 femoropopliteal lesions in 51 patients who were followed for a mean of 15 months.¹² Although the complica-

tion rate was acceptable, the cumulative clinical success rate at one year was only 19%. These poor results have been confirmed by others, and LABA is no longer being used clinically.¹³

Another endovascular technique which has been studied extensively is atherectomy. Numerous different atherectomy catheters have been described. We reported our experience with the Kensey (Trac-Wright) catheter, which is a catheter-mounted rotational atherectomy device which works by micropulverizing the atherosclerotic plaque that it encounters.¹⁴ This device was used in 46 procedures in 42 patients who were followed for a mean of 19 months. In addition to a high incidence of vessel perforation (24%), clinical success at two years was only 37%. Others have had equally discouraging results with atherectomy catheters.¹⁵

INFRAINGUINAL BYPASS

Since most infrainguinal occlusive disease is not amenable to endarterectomy, and the long-term results of endovascular techniques have been disappointing, infrainguinal bypass remains the standard for lower extremity revascularization.

The success of a bypass depends upon surgical technique, inflow, outflow, and the bypass graft or conduit. One cannot overemphasize the importance of meticulous surgical technique in handling and anastomosing blood vessels. In 1902, Alexis Carrel stressed the delicate handling of blood vessels and the meticulous coaptation of flow surfaces.¹⁶ Improvements in instruments, suture, magnification, and lighting have allowed vascular surgeons more closely to adhere to these principles.

No matter how perfect the surgical technique, however, a bypass will have limited impact on distal perfusion if there is significant inflow disease or poor distal runoff. Inflow disease needs to be addressed either preoperatively or intraoperatively. Short segment iliac stenoses can be successfully managed by angioplasty. The role of a vascular stent in this situation has not been clearly defined, although we have had a favorable experience with combined iliac angioplasty with stent placement and infrainguinal bypass.¹⁷ More diffuse inflow disease requires aortobifemoral

or extra-anatomic bypass. Little can be done to improve poor distal runoff, except to take advantage of all of the runoff which is available (sequential bypass or double distal bypass).

CHOICE OF GRAFT

The choice of bypass graft remains an area of debate,^{9,18,19,20} although autogenous vein is clearly superior to synthetic graft.²¹ The two most important components of a bypass graft are an endothelial cell lining and a compliance which is close to that of the native artery.

Endothelial cells secrete many products which prevent graft thrombosis including prostacyclin, nitric oxide, plasminogen activators, and heparin-like substances.²² Both prostacyclin and nitric oxide cause vasodilation and inhibit platelet aggregation. Plasminogen activators help regulate fibrinolysis, and the proteoglycan heparin sulfate increases the activity of anti-thrombin III. Protein S is another endothelial-derived peptide which potentiates the effect of protein C, a naturally occurring anticoagulant. Endothelial cells also express thromboresistant glycoproteins. For these reasons, endothelial cells provide the ultimate nonthrombogenic flow surface.

Compliance is the second critical determinant of graft performance. Ideally, a graft should have a compliance which is equal to that of the native vessel. A graft with low compliance impedes pulsatile flow and results in significant energy loss.²³ A compliant graft is able to absorb energy during systole and release it during diastole.²⁴ In addition, a graft with low compliance results in diminished diastolic flow, increased wave reflection at the proximal anastomosis, and increased turbulence at the distal anastomosis.^{23,24} A compliance mismatch at an anastomosis also increases the risk of false aneurysm formation. The inferior patency of synthetic grafts is thought to be related to the lack of an endothelial cell lining and the low compliance of these grafts. Although a tremendous amount of research has focused on methods of establishing an endothelial cell lining on prosthetic grafts, endothelial cell attachment to these grafts remains a major obstacle.^{25,26} In addition, graft manufacturers have been unable to create

a more compliant graft. Until a more compliant synthetic graft is available and endothelial cell attachment to grafts becomes clinically successful, autogenous vein remains the graft of choice for lower extremity revascularization. Autogenous vein transplanted into the arterial system maintains a compliance which is significantly greater than that of synthetic grafts, but less than that of native artery.²⁷ In addition, autogenous vein grafts maintain their endothelial lining.

There is significant controversy over how best to use autogenous vein. The greater saphenous vein (GSV) can be used reversed, in situ, or nonreversed. Although no differences in patency have been clearly demonstrated in comparing these different techniques of graft preparation, the best method will likely depend upon which method best preserves the endothelial cell lining and is least injurious to the vein. Injury causes the formation of scar tissue which results in a less compliant graft.

The reversed saphenous vein graft (RSVG) is subjected to tremendous stress during its harvest and implantation. Stresses include the mechanical trauma of dissection, interruption of the vasa vasorum, the trauma of hydrostatic distention, a period of warm ischemia, and new arterial hemodynamics. Many structural changes have been shown to occur both acutely and chronically in these grafts.²⁸ Acutely, these grafts show areas of significant endothelial sloughing which allows the attachment of platelets and monocytes, both of which may be involved with subsequent graft failure. In the literature, edema, focal hemorrhage, and smooth muscle cell necrosis are noted. Chronically, intimal hyperplasia develops and smooth muscle cells become replaced with variable amounts of collagen and fibroblasts. Likewise scar tissue invades the adventitial layer. These changes result in a less compliant graft.

The advantages of the in situ technique include those mentioned in the following points: (1) limited dissection is used; (2) the vasa vasorum are not interrupted; (3) the vein is only distended by normal arterial pressure; and (4) warm ischemia time is minimized. Theoretically, this should result in better endothelial preservation, less intimal and medial damage, less scar tissue formation, and thus a more compliant graft. These benefits have been demon-

strated in a dog model which compared in situ vein grafts to reversed vein grafts.²⁹ At four months the vein grafts used in situ could not be distinguished histologically from normal artery. Furthermore, in situ saphenous vein grafts (ISSVG) have been shown to be more compliant than RSVG.³⁰ An additional advantage of the in situ technique is that there is a better size match between the graft and the native artery at the proximal and distal anastomoses.

The limitations of the in situ technique are that the valves must be rendered incompetent, and major saphenous vein branches must be ligated in order to prevent arteriovenous fistulae. Valvulotomy can result in significant intimal damage, medial damage, and even vein disruption.^{31,32} Also, incompletely cut or retained valves can significantly affect graft performance.³¹ For these reasons, many surgeons prefer to expose the entire length of the vein so that valvulotomy can be performed under more controlled circumstances. The surgeon is further compelled to dissect the vein because branches of the GSV, which need to be ligated, may be difficult to localize precisely, even with the assistance of a sterile Doppler. However, extensive dissection defeats the purpose of the in situ technique. Recently, new techniques have been described for valvulotomy and occlusion of side branches which may be less injurious to the vein.^{32,33}

First, angioscopically directed valvulotomy has been shown to minimize valvulotome-induced injury and eliminate retained valve cusps.³² One of the newest valvulotomes, the Angioscopic Valvulotome Device (Baxter[®]), allows the valves to be disrupted under angioscopic control with a single pass of the catheter, thus minimizing the risk for

intimal damage (Fig. 1). In addition, the precise location of vein branches can be marked as they are identified angioscopically. Using this technique, the in situ bypass can be performed through incisions for the proximal and distal anastomoses with multiple short incisions for ligation of the branches.

Second, side branches can now be occluded using endovascular devices, further eliminating the need to dissect the vein. An electronically steerable Nitinol catheter (Catheter Research, Inc., Indianapolis, Ind.) has been used to inject platinum coils into side branches in order to occlude them (Fig. 2). Rosenthal has reported encouraging results with this technique.³³ So far, the major advantage of this technique is that the entire procedure can be performed through two incisions, thus reducing the risk of wound complications which have plagued the standard in situ bypass. There is concern that these new intraluminal devices may cause intimal injury, and further study is needed. Future endovascular systems will likely be smaller and less likely to injure the vein. Despite the theoretical advantages of the in situ technique, a prospective randomized study by Harris showed no difference in patency in comparing ISSVG and RSVG.³⁰ It is possible that these new endovascular systems will allow the vein to be prepared truly in situ, and advantages of the in situ technique may become apparent. However, currently, the RSVG is an equally acceptable graft for infrainguinal revascularization.

A third method of using the GSV is done in a nonreversed translocated fashion. Proponents of this technique argue that the real advantage of the in situ technique is the size match at the proximal and distal anastomoses.¹⁸ Although the vasa vasorum are interrupted using

this technique, there is evidence that circulation is reestablished within the wall of the vein within 72 hours.³⁴ Also, nonreversed translocated vein grafts, like ISSVG, are distended under physiologic pressure. Other advantages of this technique include no risk of missing saphenous vein branches which may form arteriovenous fistulae and a more versatile graft which can be tunneled as necessary in order to prevent kinks.

When GSV is not available, alternative sources of vein may be used. Lesser saphenous vein (LSV) is thick and easy to work with because it is subjected to the higher hydrostatic pressures in the lower extremity. However, there are disadvantages to the LSV. The vein is located posteriorly which makes it difficult to dissect out without placing the patient prone. In addition, it is a short vein. It can be used in situ for patients with isolated infrapopliteal disease.³⁵

Arm vein is another alternative source of autogenous vein. Surprisingly, the cephalic vein is almost as long as the GSV.³⁶ However, there are disadvantages to arm vein. These veins are very thin and therefore more difficult to work with. In addition, arm veins have often been injured by previous phlebotomy. The results with arm vein are inferior to those obtained with GSV, although better than those obtained with synthetic grafts.³⁷

ADJUNCTIVE TECHNIQUES

If autogenous vein is not available, then synthetic graft can be used for infrainguinal bypass. However, in 1985, Veith and coworkers conclusively demonstrated that the patency of infrapopliteal artery bypass with ePTFE grafts is significantly worse than the results with autogenous vein.²¹ At four years, the primary patency with vein

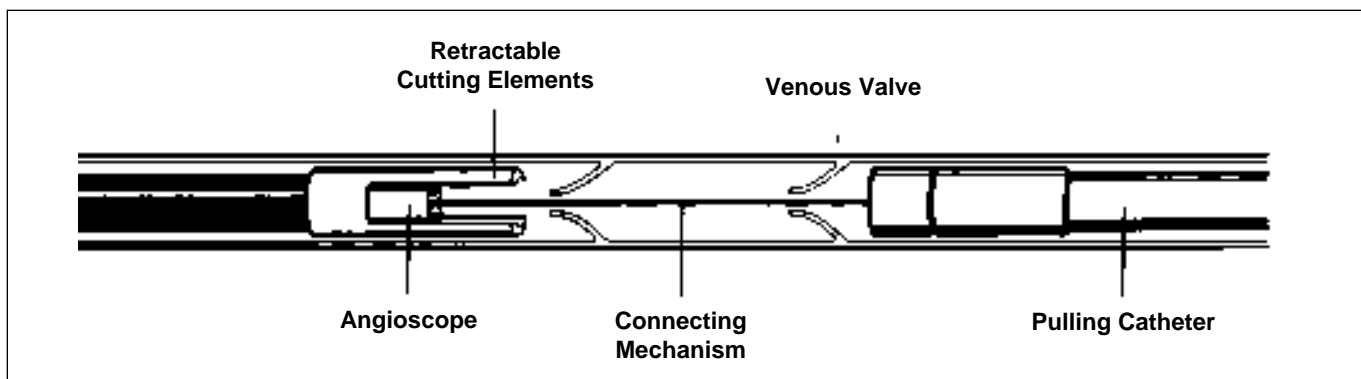


Figure 1. The Angioscopic Valvulotome Device (Baxter[®]) which allows valve disruption under angioscopic control and identification of major saphenous vein branches with a single pass of the catheter.

graft was 49%, compared to 12% with ePTFE. These poor results prompted a search for new techniques which might improve the patency of these grafts.

Ibrahim was the first to report on the use of an arteriovenous fistula

(AVF) at the distal anastomosis of an infrapopliteal bypass in order to try to improve graft patency.³⁸ The adjunctive AVF is created by making a longitudinal arteriotomy in the chosen runoff artery and in an adjacent vein. The adjacent

edges of the artery and vein are sewn together creating a common ostium, to which the distal graft is sewn. There remain some unanswered questions about this technique. The hemodynamic results of an adjunctive AVF are not fully understood. There is evidence that significant "steal" may develop.³⁹ Furthermore, there is no sound evidence that limb salvage is improved with this technique. Also, four different techniques have been described,^{38,40,41,42} and it is not clear which technique is best. Finally, this anastomotic configuration appears to be a perfect set-up for intimal hyperplasia.

A second adjunctive anastomotic technique which has been recently described is the Taylor patch. By incorporating a vein patch at the distal anastomosis of prosthetic infrapopliteal artery bypasses, Taylor was able to achieve a five-year patency of 54%.⁴³ The theoretical advantage of this technique is that there is a better compliance match at the distal anastomosis.

Another method of obtaining a better compliance match at the distal anastomosis is to use a composite graft. When limited vein is available, a prosthetic graft is sewn end-to-end to the available vein in a hand-clasp fashion in order to prevent narrowing at the anastomosis (Fig 3). The vein is then anastomosed to the distal artery. Our results with composite grafts are significantly better than with all prosthetic grafts.^{44,45}

Theoretically, another method to improve graft patency is to take advantage of all of the runoff which is available. The sequential bypass and the double distal bypass are two graft configurations which make the greatest possible use of the available outflow. Sequential bypass refers to a femorotibial bypass, with the mid-segment of the graft anastomosed side-to-side to a "blind" popliteal segment. Several authors have argued that the additional runoff through the "blind" popliteal segment will improve graft patency,^{46,47} although this has never been demonstrated in a randomized controlled series. In addition, since a sequential bypass involves bypass to two vascular beds which are in series, this configuration may not increase distal perfusion, which is the real goal of infrainguinal revascularization.

If two equally acceptable tibial vessels are available to bypass, then a double distal bypass is another option. An

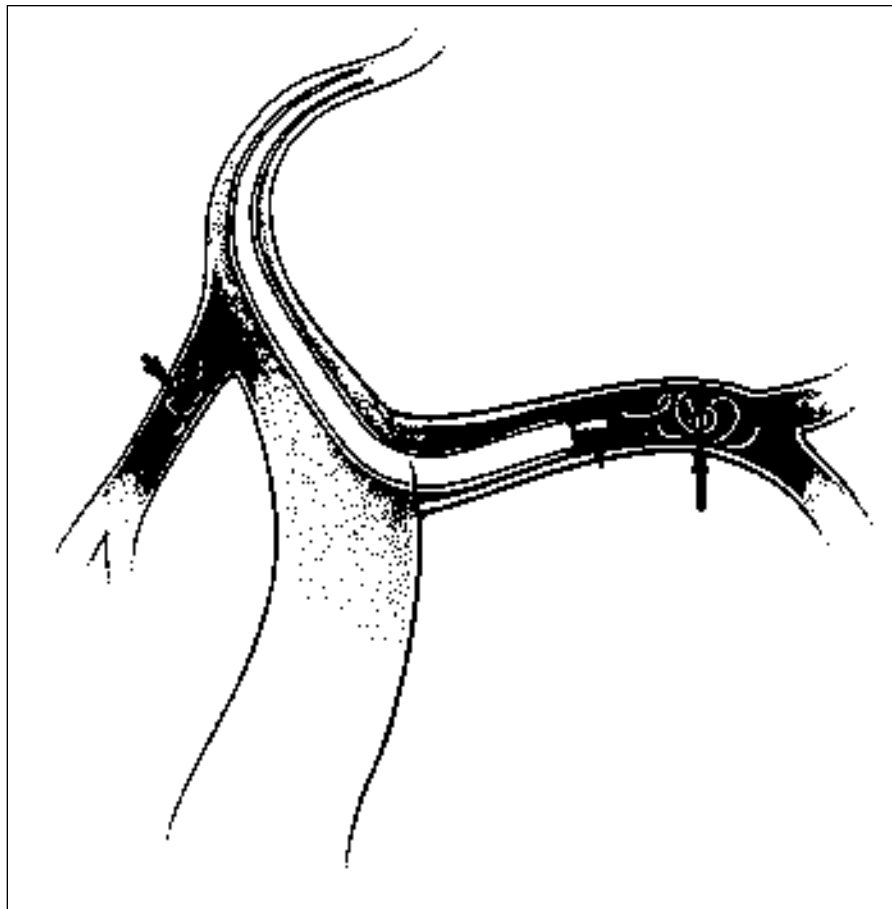


Figure 2. Intraluminal occlusion of side branches using an electronically steerable Nitinol catheter (Catheter Research, Inc.).

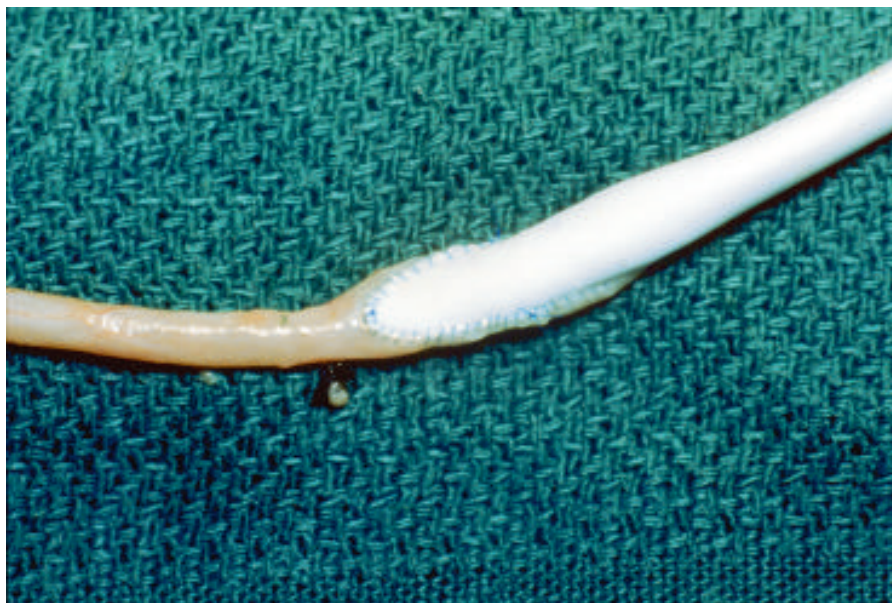

Figure 3. An ePTFE saphenous vein composite graft.

in situ femorotibial bypass can be performed, and then a separate segment of reversed vein graft can be taken from this graft to a second tibial runoff vessel. Alternatively, it is sometimes possible to use both segments of a double saphenous system in situ, with each end anastomosed to separate tibial vessels. From a hemodynamic standpoint, double distal bypass involves bypass to two vascular beds which are parallel. Theoretically, this configuration should improve distal perfusion more than a standard femorotibial bypass, although this has not been studied.

Another advance in infrainguinal revascularization has been the use of the pneumatic tourniquet for vascular control. In 1980, Bernhard described the use of the pneumatic tourniquet as a substitute for vascular clamps during lower extremity revascularization⁴⁸; however, only recently has this technique become popular.^{49,50} Advantages of the tourniquet include those mentioned in the following points: (1) the lumen of the vessel is not obliterated by vascular clamps; (2) there are no clamps cluttering the field; (3) limited dissection of the vessel is required; and (4) there is no risk of clamp-related vessel wall injury. Excellent visualization for sewing the distal anastomosis can be obtained with this technique.

Finally, in addition to advances in surgical technique, there have been advances in intraoperative graft surveillance. Ideally, surgeons would like their patients to leave the operating room with a technically perfect anastomosis. Intraoperative angiography has been the standard method of detecting technical errors at the time of surgery. However, newer techniques including intraoperative duplex scanning and angioscopy may offer certain advantages. We have found intraoperative duplex scanning useful in the detection of stenoses, arteriovenous fistulae, uncut valve cusps, thrombus, intimal defects, and low graft velocity.⁵¹ This technique allows the surgeon to focus on areas of concern and allows one to determine the functional significance of a lesion.

Angioscopy is becoming increasingly popular as a method of intraoperative graft surveillance. The advantage of angioscopy is that it allows direct, three-dimensional visualization of the entire graft and anastomoses. It can detect all of the defects previously described. A blind comparison of angiography,

angioscopy, and duplex scanning by Gilbertson showed that angioscopy was the most accurate method of intraoperative graft surveillance.⁵² Potential disadvantages of angioscopy include cost and the concern that it may cause endothelial injury.

CONCLUSIONS

In summary, a tremendous number of new techniques have been described for infrainguinal revascularization. Endovascular techniques, including laser-assisted balloon angioplasty and atherectomy, have had disappointing results. However, lessons learned from these endeavors have allowed the development of new endovascular instruments which may prove useful. Bypass with autogenous vein remains the standard for infrainguinal revascularization. Several adjunctive techniques have been described in order to try to improve the patency of synthetic grafts. Graft manufacturers will continue to try to make a more compliant graft; and basic science labs, including our own, continue to pursue endothelial cell seeding of grafts. Finally, improved intraoperative graft surveillance with duplex scanning and angioscopy make it possible to detect even subtle technical defects before the patient leaves the operating room. Continued efforts at improving the results of infrainguinal revascularization should result in less limb loss and an improved quality of life for these patients. **STI**

REFERENCES

1. Imparato AM, Bracco A, Kim GE. Comparison of three techniques for femoropopliteal arterial reconstruction. *Ann Surg* 1973;117:375.
2. Dotter CT. Cardiac catheterization and angiographic techniques of the future. *Cesk Radiol* 1965;19:217-36.
3. Dotter CT, Judkins MP. Transluminal treatment of arteriosclerotic obstruction: Description of a new technique and a preliminary report of its application. *Circulation* 1974;30:654-70.
4. Grüntzig A, Hopff H. Perkutane rekanalisation chronischer arterieller Verschlüsse miteinem neuen Dilatationskatheter: Modification der Dotter-Technik. *Dtsch Med Wochenschr* 1974;99:2502-5.
5. Wilson SE, Wolf GL, Cross AP. Percutaneous transluminal angioplasty versus operation for peripheral arteriosclerosis. *J Vasc Surg* 1989;9:1-9.
6. Gallino A, Hahler F, Probst P, et al. Percutaneous transluminal angioplasty of the

- arteries of the lower limbs: A five-year follow-up. *Circulation* 1984;70(4):619-23.
7. Johnston KW, Rae M, Hoss-Johnston SA, et al. Five-year results of a prospective study of percutaneous transluminal angioplasty. *Ann Surg* 1987;206(4):404-13.
8. Veith FJ, Gupta SK, Samson RH, et al. Progress in limb salvage by reconstructive arterial surgery combined with new or improved adjunctive procedures. *Ann Surg* 1981;194:386-400.
9. Taylor LM, Edwards JM, Porter JM. Present status of reversed vein bypass grafting: Five-year results of a modern series. *J Vasc Surg* 1990;11:193-206.
10. Sanborn TA, Greenfield AJ, Guben JK, et al. Human percutaneous and intraoperative laser thermal angioplasty: Initial clinical results as an adjunct to balloon angioplasty. *J Vasc Surg* 1987;5:83-90.
11. Rosenthal D, Pesa FA, Gottsegen WL, et al. Thermal laser-assisted balloon angioplasty of the superficial femoral artery: A multicenter review of 602 cases. *J Vasc Surg* 1991;14:152-9.
12. Feinberg RL, Wheeler JR, Gregory RT, et al. Initial results and subsequent outcome of laser thermal-assisted balloon angioplasty of 56 consecutive femoropopliteal lesions. *Am J Surg* 1990;160:166-170.
13. Seeger JM, Abela GS, Silverman SH, et al. Initial results of laser recanalization in lower extremity arterial reconstruction. *J Vasc Surg* 1989;9:10-7.
14. Cull DL, Feinberg RL, Wheeler JR, et al. Experience with laser-assisted balloon angioplasty and a rotary angioplasty instrument: Lessons learned. *J Vasc Surg* 1991;14:332-9.
15. Ahn SS, et al. Peripheral atherectomy with the rotablator: A multicenter report. *J Vasc Surg* 1994;19:509-15.
16. Carrel A. La technique opératoire des anastomoses vasculaires et la transplantation des viscères. *Lyon Medical* 1902;98:859-64.
17. DeMasi RJ, Snyder SO, Wheeler JR, et al. Intraoperative iliac artery stents: Combination with infra-inguinal revascularization procedures—Preliminary results. *The American Surgeon*. In press.
18. Batson RC, Sottiturai VS. Nonreversed and in situ vein grafts. Clinical and experimental observations. *Ann Surg* 1985;201(6):771-9.
19. Leather RP, Shah DM, Karmody AM. Infrapopliteal arterial bypass for limb salvage: Increased patency and utilization of the saphenous vein used "in situ." *Surgery* 1981;90(6):1000-8.
20. Fogle MA, Whittemore AD, Couch NP, et al. A comparison of in situ and reversed vein grafts for infrainguinal reconstruction. *J Vasc Surg* 1987;5:46-52.
21. Veith FJ, Gupta SK, Ascer E, et al. Six-year prospective multicenter randomized comparison of autologous saphenous vein and expanded polytetrafluoroethylene grafts in infrainguinal arterial reconstructions. *J Vasc Surg* 1986;3:104-14.
22. Davies MG, Hagen P. The vascular endothelium. A new horizon. *Ann Surg* 1993;218(5):593-609.
23. Kidson IG, Abbott WM. Low compliance

- and arterial graft occlusion. *Circulation* 1978;58(3) Suppl 1:I1-4.
24. Baird RN, Abbott WM. Pulsatile blood-flow in arterial grafts. *Lancet* 1976;2:948-9.
25. Welch M, Durrans D, Carr HM, et al. Endothelial cell seeding: A review. *Ann Vasc Surg* 1992;6(5):473-84.
26. Stansby G, Berwanger C, Shukla N, et al. Endothelial cell seeding of vascular grafts: Status and prospects. *Cardiovasc Surg* 1994;2(5):543-8.
27. Abbott WM, Bouchier-Hayes DJ. The role of mechanical properties in graft design. In: Dardik H, ed. *Graft materials in vascular surgery*. Miami: Symposia Specialist; 1978. p 59-78.
28. Fuchs JC, Mitchener JS, Hagen P. Postoperative changes in autologous vein grafts. *Ann Surg* 1978;188(1):1-15.
29. Buchbinder D, Singh JK, Karmody AM, et al. Comparison of patency rate and structural changes of in situ and reversed vein arterial bypass. *J Surg Res* 1981;30:213-22.
30. Harris PL, How TV, Jones DR. Prospective randomized clinical trial to compare in situ and reversed saphenous vein grafts for femoropopliteal bypass. *Br J Surg* 1987;74:252-5.
31. Donaldson MC, Mannick JA, Whittemore AD. Causes of primary graft failure after in situ saphenous vein bypass grafting. *J Vasc Surg* 1992;15:113-20.
32. Miller A, Stonebridge PA, Tsoukas AI, et al. Angioscopically directed valvulotomy: A new valvulotome and technique. *J Vasc Surg* 1991;13:813-21.
33. Rosenthal D, Dickson C, Rodriguez FJ, et al. Intrainguinal endovascular in situ saphenous vein bypass: ongoing results. *J Vasc Surg* 1994;20:389-95.
34. Wyatt AP, Rothnie NG, Taylor GW. The vascularization of vein-grafts. *Br J Surg* 1964;51:378-81.
35. Ouriel K. The posterior approach to popliteal-crural bypass. *J Vasc Surg* 1994;19:74-80.
36. Andros G, Harris RW, Dulawa LB, et al. The use of arm veins as lower extremity arterial conduits. In: Kempczinski RF, ed. *The ischemic leg*. Chicago: Year Book Medical; 1985. p 419-36.
37. Schulman ML, Badhey MR. Late results and angiographic evaluation of arm veins as long bypass grafts. *Surgery* 1982;92(6):1032-41.
38. Ibrahim IM, Sussman B, Dardik I, et al. Adjunctive arteriovenous fistula with tibial and peroneal reconstruction for limb salvage. *Am J Surg* 1980;140:246-51.
39. Snyder SO, Wheeler JR, Gregory RT, et al. Failure of arteriovenous fistulas at distal tibial bypass anastomotic sites. *J Cardiovasc Surg* 1985;26:137-42.
40. Paty PS, Shah DM, Saifi J, et al. Remote distal arteriovenous fistula to improve infrapopliteal bypass patency. *J Vasc Surg* 1990;11:171-8.
41. Jacobs MJ, Reul GJ, Gregoric ID, et al. Creation of a distal arteriovenous fistula improves microcirculatory hemodynamics of prosthetic graft bypass in secondary limb salvage procedures. *J Vasc Surg* 1993;18:1-9.
42. Moody AP, Fagih SA, Edwards PR, et al. The use of an adjunctive arterio-venous shunt in prosthetic femoro-crural bypass. *Eur J Vasc Surg* 1991;5:327-32.
43. Taylor RS, Loh A, McFarland RJ, et al. Improved technique for polytetrafluoroethylene bypass grafting: Long-term results using anastomotic vein patches. *Br J Surg* 1992;79:348-54.
44. Snyder SO, Gregory RT, Wheeler JR, et al. Composite grafts utilizing polytetrafluoroethylene-autogenous tissue for lower extremity arterial reconstructions. *Surgery* 1981;90(5):881-8.
45. Gregory RT, Raithel D, Snyder SO, et al. Composite grafts: An alternative to saphenous vein for lower extremity arterial reconstruction. *J Cardiovasc Surg* 1983;24:53-7.
46. Flinn WR, Ricco JB, Yao JS, et al. Composite sequential grafts in severe ischemia: A comparative study. *J Vasc Surg* 1984;1:449-54.
47. McCarthy WJ, Pearce WH, Flinn WR, et al. Long-term evaluation of composite sequential bypass for limb-threatening ischemia. *J Vasc Surg* 1992;15:761-70.
48. Bernhard VM, Boren CH, Towne, JB. Pneumatic tourniquet as a substitute for vascular clamps in distal bypass surgery. *Surgery* 1980;87(6):709-13.
49. Collier PE. Atraumatic vascular anastomoses using a tourniquet. *Ann Vasc Surg* 1992;6:34-7.
50. Wagner WH, Treiman RT, Cossman DV, et al. Tourniquet occlusion technique for tibial artery reconstruction. *J Vasc Surg* 1993;18:637-47.
51. Cull DL, Gregory RT, Wheeler JR, et al. Duplex scanning for the intraoperative assessment of infrainguinal arterial reconstruction: A useful tool? *Ann Vasc Surg* 1992;6:20-4.
52. Gilbertson JJ, Walsh DB, Zwolak RM, et al. A blinded comparison of angiography, angioscopy, and duplex scanning in the intraoperative evaluation of in situ saphenous vein bypass grafts. *J Vasc Surg* 1992;15:121-9.