

Hysteroscopic Myometrial Biopsy to Diagnose Adenomyosis and Its Clinical Application

ARTHUR M. McCAUSLAND, M.D., F.A.C.O.G.
DEPARTMENT OF OBSTETRICS AND GYNECOLOGY
SUTTER MEDICAL GROUP – SUTTER COMMUNITY HOSPITAL
CLINICAL PROFESSOR, THE UNIVERSITY OF CALIFORNIA MEDICAL SCHOOL AT DAVIS
SACRAMENTO, CALIFORNIA

With the advent of hysteroscopy, the diagnosis of intrauterine pathology has greatly improved. Endometrial polyps and submucous fibroids are easily visualized; however, normal appearing cavities have been reported in over 50% of patients with menorrhagia.¹ For this reason a myometrial biopsy was originally developed to see what percentage of these patients with a hysteroscopically normal-appearing cavity might have adenomyosis.¹ The myometrial biopsy was taken from the posterior endometrial wall with a 5-mm loop electrode at the time of operative hysteroscopy. The specimen was sent to two pathologists, Dr. Anthony Mathios and Dr. John Abele, to see if adenomyosis could be diagnosed. It was found that with proper orientation, the amount of endometrial penetration into the myometrium could be measured. Therefore, superficial and deep adenomyosis can be diagnosed with a myometrial biopsy. But for a single myometrial biopsy to have any clinical relevance, two questions must be answered. First, does a single myometrial biopsy showing adenomyosis represent the entire endometrial cavity? Second, does the deepest adenomyosis occur in any certain area of the myometrial wall?

To answer these questions, the world literature regarding adenomyosis was reviewed.¹ It was found that adenomyosis is usually a diffuse condition. If one area has it, typically the entire endometrial cavity is also involved. This is in contrast to the less frequently found localized adenomyosis (adenomyoma) which appears more like a

fibroid. The world literature also revealed that the posterior endometrial wall is usually the area most severely involved with adenomyosis. To confirm this, hysteroscopic anterior and posterior myometrial biopsies were performed on 15 of my patients. It was found that if one of these biopsies revealed adenomyosis, it was also

found on the other biopsy. Thirty hysterectomy specimens were also studied and the depth of endometrial penetration was measured in both the anterior and posterior uterine wall. It was found that adenomyosis is a diffuse process which usually involves the entire uterine cavity. Both the anterior and posterior walls were affected, but

the deepest penetration was almost always in the posterior wall. Therefore, a single myometrial biopsy of the posterior uterine wall is not only diagnostic of adenomyosis but also represents the area most severely involved (with the deepest endometrial penetration into the myometrium).

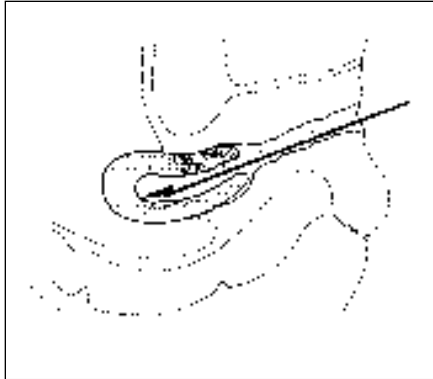


Figure 1. Myometrial biopsy being taken from the posterior uterus during operative hysteroscopy. A 5-mm loop electrode is removing a 2- to 3-cm long specimen.

Knowing this, 50 patients with menorrhagia requiring operative hysteroscopy were studied.¹ Most patients had regular ovulatory periods confirmed by either a luteal phase endometrial biopsy showing secretory endometrium or a serum progesterone level in the ovulatory range. All patients found to have dysfunctional uterine bleeding were cycled with progesterone. They were included in the study only if this did not correct the problem. All patients received a trial regime of nonsteroidal anti-inflammatory medication before further therapy. A complete blood count and panel of thyroid tests with thyroid stimulating hormone were included in the evaluation. At the time of operative hysteroscopy, a posterior myometrial biopsy was performed to measure the amount of endometrial penetration into the myometrium. In patients with a hysteroscopically normal-appearing cavity (without polyps or

submucous fibroids), the amount of endometrial penetration into the myometrium correlated nicely with the severity of menorrhagia. A control group of 30 patients with normal periods were matched by age, gravity, and parity with the study group. These patients were requiring hysterectomies for reasons other than abnormal bleeding, such as prolapse or carcinoma in situ of the cervix. The depth of endometrial penetration in the anterior and posterior walls were studied. It was found that the average endometrial penetration in the posterior wall was 0.8 mm, and this was almost greater than that found in the anterior which had an average depth of 0.46 mm. Therefore, endometrial penetration greater than 1 mm was found to be associated with significant menorrhagia. The depth of endometrial penetration correlated closely with the degree of menorrhagia when the uterine cavity appeared nor-

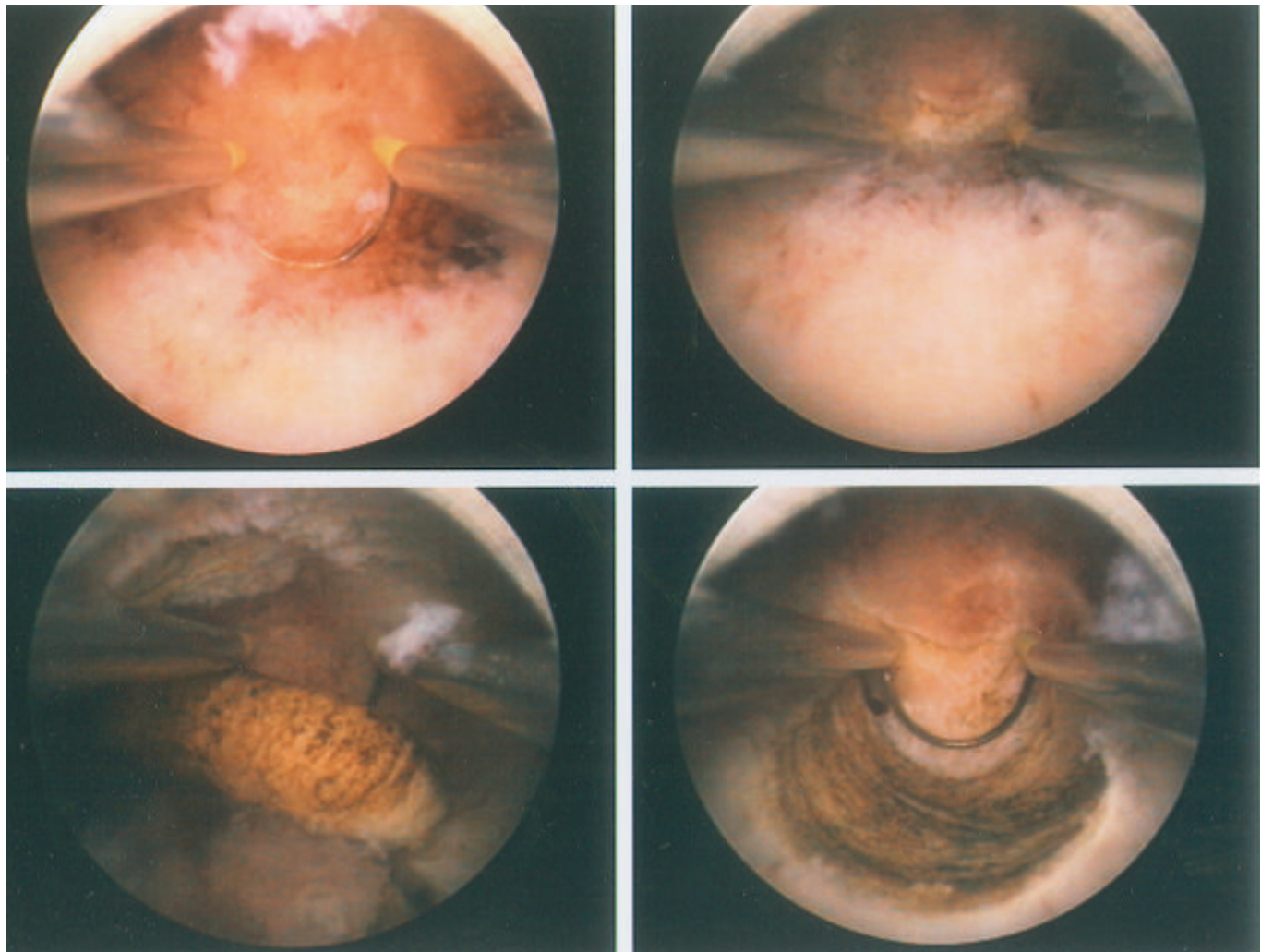


Figure 2. Hysteroscopic picture of a myometrial biopsy using a 5-mm loop electrode. Upper left: 5-mm loop electrode fully extended into the upper endometrial cavity. Upper right: the 5-mm loop electrode completely buried into the posterior uterine wall using 70 watts of cutting current. Lower left: the myometrial biopsy specimen shown floating freely in the endometrial cavity. Lower right: picture of the myometrial biopsy bed.

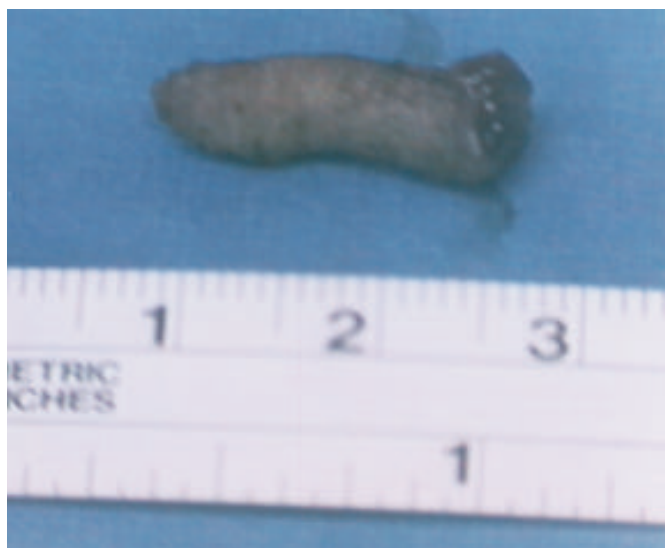

Figure 3. Myometrial biopsy specimen after removal from the uterus.

mal hysteroscopically (i.e., without gross polyps or submucous fibroids).

Others have attempted to diagnose adenomyosis using different techniques but with less success than using a hysteroscopic myometrial biopsy. Popp et al. used an automatic cutting needle to sample the myometrium.² In 34 patients with clinical symptoms of adenomyosis, 70 myometrial biopsies were performed during laparoscopy, and ultrasonographically guided vaginal myometrial biopsy was performed in 6 patients without complications. The sensitivity of a single myometrial sample for diagnosing adenomyosis ranged from 8% to 18.7%. Pasquinucci et al. used a biopsy needle to take a single specimen along with median line in the upper third of the posterior uterine wall in 45 women under 40 years old undergoing laparoscopy or conservative surgery at laparotomy.³ Adenomyosis was demonstrated in 5 women (11%). In my study of 50 patients with menorrhagia who had a hysteroscopically normal-appearing cavity, 33 (66%) had significant adenomyosis defined as greater than 1 mm of endometrial penetration into the posterior myometrial wall.¹

TECHNIQUE

A myometrial biopsy is performed during operative hysteroscopy. The patients were scheduled immediately following a menstrual period because the endometrial lining is thin at that time. A laminaria tent was inserted at least four hours before the surgery to facilitate cervical dilation. After the patient is anesthetized, the cervix is

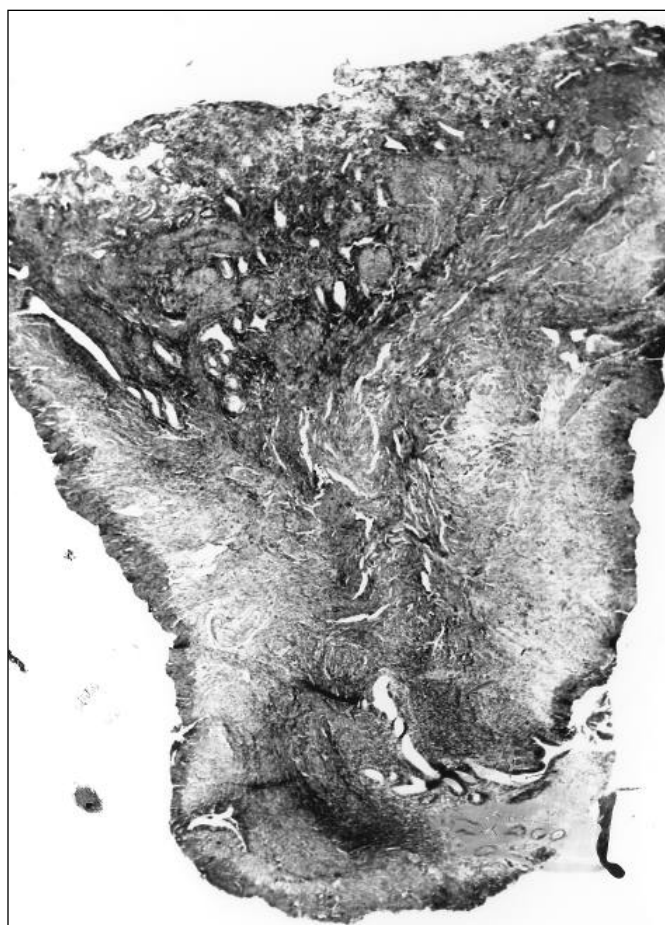


Figure 4. Histology of cross section of myometrial biopsy (scanning power) demonstrating deep adenomyosis.

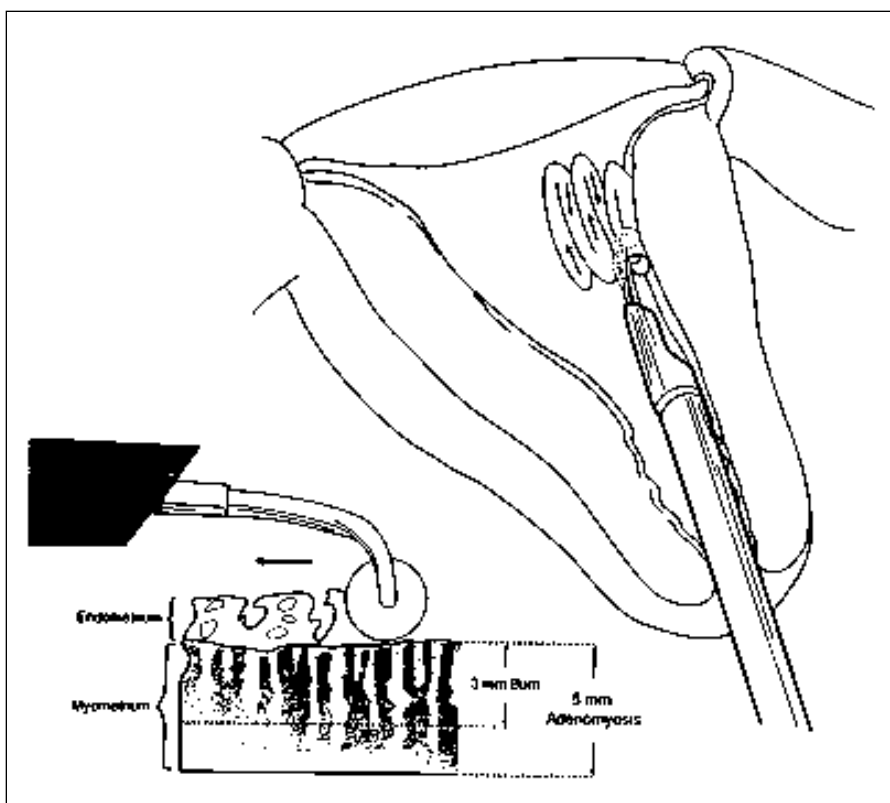


Figure 5. Roller ball endometrial ablation. Three-millimeter burn potentially leaving endometrial glands under the scar in patients with 5-mm deep adenomyosis.

dilated to a 31 French, and a 26 French operative hysteroscope is inserted. Sorbitol is used as a distention media. The myometrial biopsy is taken with the 5-mm loop electrode from the posterior wall (Figs. 1, 2). The loop electrode is extended fully to the upper portion of the endometrial cavity with 70 watts of pure cutting current. The loop is completely imbedded 5 mm deep into the posterior myometrial wall near the fundus, and a 2 to 3 cm segment is resected. The parallel supporting bars of the loop electrode prevent deeper penetration into the myometrium. The biopsied tissue usually floats freely in the endometrial cavity and can easily be grasped with the loop and retracted up against the hysteroscopic sheath for removal. Bleeding from the biopsy site is rare and can be handled by using the coagulating current through the loop electrode. This specimen is sent to the pathologist for evaluation. *It is absolutely critical that you notify the pathologist about what you expect from the tissue evaluation.* It is often helpful to copy the following paragraph which describes how the pathologist should orient the myometrial biopsy.

The specimen, which is usually 2 to 3 cm in length, 5 mm in width, and 5 mm in depth, is fixed completely (Fig. 3). The endometrial surface is the flat portion of the specimen, and the myometrial surface is either rounded or convex, which often shows variable blackish coagulation markings from the loop electrode cautery.

The accuracy of adenomyosis measurements requires proper orientation. The basalis surface of the myometrium is inked with one of the standard marking dyes, and the specimen is then serially cross-divided perpendicular to the endometrial surface. Usually one or

two of these cross sections can be recognized by visual inspection as optimally orientable and minimally coagulated. These are stained a different color on the opposed deep myometrial surface, and then both stained and unstained pieces are submitted between imbedding sponges in cassette for routine histology and hematoxylin and eosin staining (Fig. 4).

Using a microscope fitted with a micrometer, the distance between the base of the deepest penetrating gland and the endometrial-myometrial junction is measured. This distance is recorded in millimeters and mentioned in the final diagnosis.

COMPLICATIONS OF MYOMETRIAL BIOPSIES

There were no immediate or long-term complications of myometrial biopsies. Bleeding from the biopsy site is rare and can be controlled with the coagulating current using the loop electrode. No perforations occurred and are unlikely if proper technique is followed. A premenopausal posterior uterine wall is between 1.5 and 2 cm (15 to 20 mm) thick. The loop electrode used for the biopsy is only 5 mm deep. Although hysteroscopic magnification makes it appear deeper, only one quarter to one-third of the wall is being biopsied.

Ten hysterectomies have been performed for persistent menorrhagia three to nine months after myometrial biopsy. There were no uterine wall defects seen at the biopsy site and no uterine adhesions.

CLINICAL SIGNIFICANCE

A myometrial biopsy to determine the depth of endometrial penetration

into the myometrium (adenomyosis) has clinical significance. First, it helps the clinician make a more accurate diagnosis when evaluating menorrhagia, especially in patients with hysteroscopically normal-appearing intrauterine cavities. If a thorough curettage fails to correct the menorrhagia, a myometrial biopsy showing adenomyosis at the time of surgery clarifies the issue.

Second, if menorrhagia persists after complete hysteroscopic resection of endometrial polyps or submucous fibroids, a myometrial biopsy showing adenomyosis can also explain this dilemma.

Third, an ongoing study is demonstrating that patients without or with only minimal endometrial penetration less than 2 mm deep (superficial adenomyosis) had excellent results from endometrial ablations. Patients with deep endometrial penetration over 2 mm deep (deep adenomyosis) usually had persistent problems and should be offered hysterectomy over repeat ablation. Endometrial glands left under a scar could not only bleed and cause pain but also have malignant potential (Fig. 5). This scar could delay bleeding and the diagnosis of endometrial cancer.

Routine myometrial biopsy at the time of operative hysteroscopy should be added to our diagnostic armamentarium. **STI**

REFERENCES

1. McCausland AM. Hysteroscopic myometrial biopsy: its use in diagnosing adenomyosis and its clinical application. *Am J Obstet Gynecol* 1992;166:1619-1628.
2. Popp LW, Schwiedessen JP, Gaetje R. *Am J Obstet Gynecol* 1993;169:546-549.
3. Pasquinucci G, Pittino R, Carcione R. Contributo allo studio dell'adenomiosi: le biopsie transmiometriali. *Ann Ost Gin Med Perin* 1991;112:91.